

Case Report

Gastric and Esophageal Duplication in Pediatric Patients: Case Report

Bucio VM and Valdés JCL*

ISSSTE, Ed 1953 University Av, 21 Depto1002, Mexico

*Corresponding author: Julio César López-Valdés, Medical Director, ISSSTE, Ed 1953 University Av, 21 Depto1002, Mexico, Tel: (5255) 5902-9446; E-mail: jc.lopez@live.com

Rec date: Feb 24, 2016 Acc date: Aug 08, 2016 Pub date: Aug 14, 2016

Abstract

Introduction: Gastric duplication is a rare malformation, represents 7 to 8% of digestive duplications; is attributed to a failure during embryonic period. Usually are asymptomatic and constitute an accidental finding by imaging techniques. The main objective of this paper analyzes the gastrointestinal tract duplications and inform about an unusual clinical case.

Clinical Case: Female newborn, with perinatal history of right ovary adnexal tumor, diagnosed at 34 weeks of pregnancy by ultrasound. Laparoscopic approach for adnexal tumor resection was performed at 16 days of life but during the procedure, were not displayed any ovarian cyst or uterine alterations. Was found an enteric cyst located in the posterior wall of stomach at fundus and left body region, corresponding to gastric duplication; also was noted esophageal replica. The accessory stomach and the enteric cyst were resected (15 x 12 cm approx.); also was performed anastomosis of the replicated distal esophagus to the fundus of true stomach accompanied of modified Stamp technique gastrostomy. After 24 hours of postoperative, enteral feeding was administered successfully without complications.

Conclusion: The required surgical procedure is extremely variable and depends such the size and location of duplication as if there are complications or heterotopic mucosa associated. The goals of surgery are completely eliminate the anomaly and mucosa added without compromising the function of the remaining intestine.

Keywords: Gastrointestinal duplication; Digestive tract; Cyst

Introduction

Gastrointestinal tract duplications are a rare congenital conditions, have been described using different nouns as "enterocistom", "enterogenous cysts", "accessory organs", etc. Although are attributed to failures during the primitive gut differentiation at embryonic period, the real etiology remains unknown [1,2].

This kind of abnormalities can occur anywhere in the digestive tract and even in the respiratory or genitourinary tract [1,2]; the approximate incidence ranges are 1: 4500 to 1: 10,000 with male predominance for the general population. In the major number of cases, are incidentally diagnosed during pediatric stages through radiological imaging studies or endoscopy. The presences in adults are

associated with malignant transformation. Despite the "universal" distribution, the GI tract is the most common site of occurrence (60-75% of total duplications), in where the distal ileum represents 35% of cases and esophagus (20%). Other sites include duodenal appearance (5-7%), stomach (2-8%) and, biliary tract, pancreas and appendix [1-5].

Here we report the incidental finding of an esophageal duplication accompanied by accessory stomach in a term newborn, which was diagnosis by the use of ultrasound images during antenatal care.

Clinical Case

Female newborn, with perinatal history of right ovary adnexal tumor, diagnosed at 34 weeks of pregnancy by ultrasound. After birth, new imaging studies (Figure 1) were performed, including ultrasound study which reported: "Giant left adnexal cyst with 80 mm in diameter, also an intra-ovarian right cyst with normal uterus".

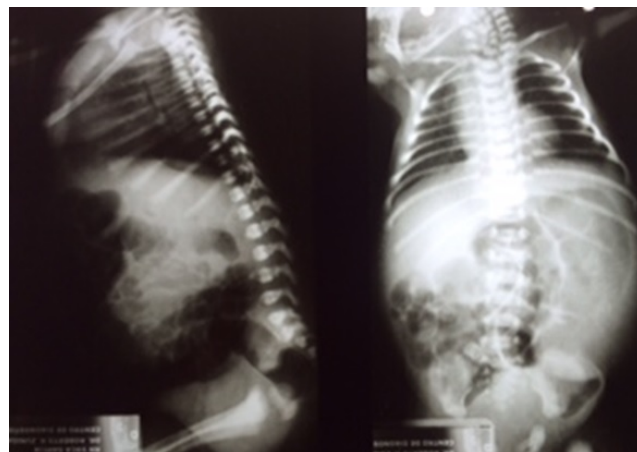

Figure 1: AP and lateral radiographs of the chest and abdomen in which poor air distribution is observed inside the abdomen with probable gastric enlargement

Laparoscopic approach for adnexal tumor resection was performed at 16 days of life but during the procedure, were not displayed any ovarian cyst or uterine alterations.

The surgical team decided to perform a midline infra umbilical and supra umbilical incision to define the mass. Was found an enteric cyst located in the posterior wall of stomach at fundus and left body region (Figure 2), corresponding to gastric duplication.

Also, was noted esophageal duplication, for that reason an orogastric tube of 10 cm was introduced at the proximal esophageal portion, for the identification of the pathway; but was not possible to detect the origin of the esophageal replica (Figure 3).

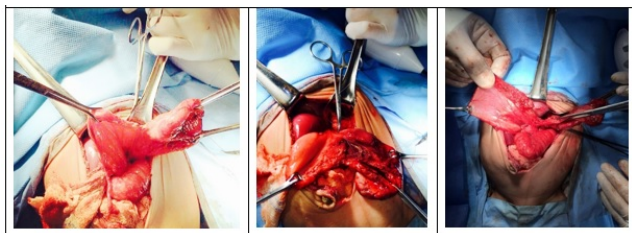


Figure 2: Surgical event in where the complete gastric duplication was evidenced also is possible to observe the second esophagus.

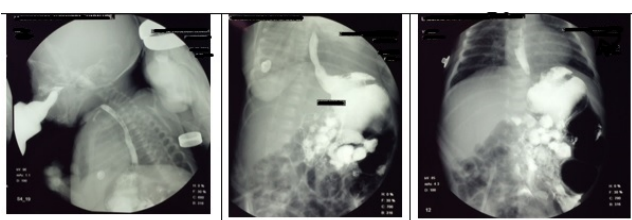


Figure 3: Esophagus-gastro duodenal series in which a normal swallowing mechanism, without passage of the contrast medium into the airways, with normal traffic in oral and pharyngeal phase is observed. The esophagus is normal in position, peristalsis and contours. No movement or presence of leakage of contrast into other structures is observed. No signs of hiatal hernia. Gastric emptying is apparently normal. The angle of Hiss is open, which probably favors a reflux, the mucosal contours of the stomach and duodenum is normal. No areas of blockage in pylorus or duodenum are identified. The location of the duodenal jejunal angle is normal and there is no data to suggest poor intestinal rotation. The study was performed under fluoroscopic and static X-rays

Discussion

As is impossible to clarify the different locations and all associated to a single theory, there are several embryonic theories to explain the gastrointestinal duplications [1-5].

According to the evidence on the initial development of the digestive tract, the primitive gut gives rise to three parts: foregut, mid gut and hindgut. At the same time, these structures differ in the organs of the gastrointestinal tract, respiratory and urogenital tract [3].

The theory proposed by Bremer, postulates that the embryonic gastrointestinal tract suffers disproportionately growth causing a buildup of intestinal epithelial cells, which suffer vacuolization coming to merge and form a new lumen. If some vacuoles failed to bind along the longitudinal axis a cyst surrounded by muscle layers is formed resulting in gastrointestinal duplication. However, this hypothesis explains only the aberrations occurring in the foregut [3-8].

Some other theories that might explain gastric duplications are: "The theory of the split notochord" or "doubles notochord" both hypotheses suggest a defect at the fusion level of ectoderm and endoderm accompanied by the formation of a double notochord outline [2,3,6].

There are also less significant assumptions such as "the theory of intrauterine vascular accident", it proposes the gastrointestinal duplication as consequence of an incomplete intestinal infarction resulting in the division of a viable portion of intestine with parallel development similar to the original organ [3-5].

Is noteworthy that there are two possible presentations, can manifest as cystic structures (spherical shape) or tubular structures covered by epithelium (usually ectopic) accompanied by smooth muscle wall. Are attached to the mesenteric border of the digestive tract, with which it shares vascularization [2,4,6,7,9]. Spherical duplications rarely communicate with the lumen of the gastrointestinal tract, while the tubular, albeit much more infrequent, generally do [4,6,7,9,10]. Three quarters of the gastrointestinal duplications correspond to cysts with no communication to the intestinal lumen [11].

Duplicity of the esophagus is the second most common gastrointestinal duplications (1:3000 to 1:4500 live births), corresponding to 15-21% of the total cases, are presented more common in men, approximately 60% is located in the distal third [4,6,12,13]

The esophagus can be divided into three segments: the upper or cervical esophagus (23%), middle (17%) and lower (60%) [4,13].

According Berrocal13, the complete duplication of the esophagus is an extremely rare malformation, often associated with gastric duplication. In addition, visualization of the complete segment doubled in the tubular form; commonly it depends on their communication with the normal esophagus or stomach, and observed during the surgical treatment of gastric component, as happened in our case.

Meanwhile the gastric duplication represents 7-8% of gastrointestinal duplications, but unlike other enteric duplications, they are more common in women [2,13]. The clinical presentation is varied (Figure 4), they may appear as the duplication of the entire stomach, or presence as a small intramural cysts below the external muscle of the stomach wall.

The clinical manifestations are variable depending on certain factors such as anatomical level involved, mass effect, tissue heterotopia, specific complications related and other abnormalities associated. However as the lesion grows, compressive symptoms can occur as a result of mass to neighboring structures such as dysphagia, vomiting, cough, wheezing and dyspnea [1,4,6,7,9,12,14-16].

In recent years there have been reports of gastrointestinal bleeding in adults associated with heterotopic mucosa secondary to enteric cysts undiagnosed [16].

The diagnosis is determined by abdominal ultrasound and computed tomography, which allows you to define the location of the mass and relations with neighboring structures [1-15].

Prenatal diagnosis is extremely rare; Correia-Pinto, et al. [17] communicate about less than 20 cases in the English-speaking literature for prenatal findings, but in only one case was thought gastrointestinal duplication cyst; in the other reports the initial diagnosis was obstruction, biliary tract abnormalities, neuroblastoma, renal cyst or gastric teratoma [17,18].

The differential diagnosis includes gastrointestinal or urinary tract defects, liver or bile duct cyst, splenic or mesentery cyst, neuroblastoma and ovarian cyst [17].

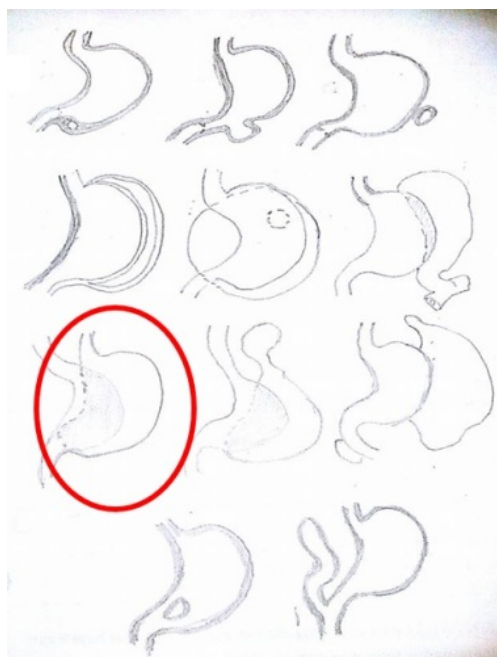


Figure 4: Different types of gastric duplications identified.

As in most cases, despite the findings in the prenatal ultrasound, there was no suspicion of gastrointestinal duplication cyst. The presumptive diagnosis was an ovarian cyst which agrees with those reported in the literature.

Once the diagnosis is established, surgical correction should be performed, due to three reasons: 1) the majority of patients require surgery for relief of symptoms, 2) eliminating the risk of perforation and bleeding caused by heterotopic mucosa cyst in itself; 3) have been reports of the development of carcinoma in the cyst lining [3].

Conclusion

The goals of surgery are completely eliminate the anomaly and mucosa added without compromising the function of the remaining intestine.

The required surgical procedure is extremely variable and depends such the size and location of duplication as if there are complications or heterotopic mucosa associated.

Acknowledgements

We would like to express our sincere gratitude to the Hospital General de Occidente; Guadalajara, Jalisco; especially to the Dr. Francisco Antonio Gallardo-Meza chief of pediatric surgery service and to Dr. Sayani Valdez-Villarruel pediatric intensivist.

References

1. Stock F, Cammarata-Scalisi F, Petrosino P, Arenas-de Sotolongo A, Milano M, et al. (2010) Duplicación gástrica. Reporte de un

caso y revisión de la literatura. *Acta Gastroenterol Latinoam* 40: 258-263

2. Navarrete-Pérez JJ, Cravioto-Villanueva A, Soria-Céspedes D (2012) Quiste de duplicación gástrica. Informe de un caso. *Rev Esp Patol* 45: 96-99
3. Hackam DJ, Zalev A, Burnstein M, Rotstein OD, Koo J (1997) Enteric duplication in the adult, derived from the foregut, midgut and hindgut: presentation, patterns and literature review. *CJS* 40: 129-133.
4. Del Razo R, Gómez A, Salcedo M, Velásquez R. Quiste de duplicación esofágica. Informe de un caso y revisión de la literatura. *Acta Pediatr Mex* 2010;31(3):108-114.
5. Park JY, Her KH, Kim BS, Maeng YH (2014) A completely isolated intestinal duplication cyst mimicking ovarian cyst torsion in an adult. *World J Gastroenterol* 20: 603-606.
6. Patiño Mayer J, Bettolli M (2014) Alimentary tract duplications in newborns and children: Diagnostic aspects and the role of laparoscopic treatment. *World J Gastroenterol* 20: 14263-14271
7. Lee JU, Kim JO, Kim SJ, Sul HJ (2010) Completely Isolated Enteric Duplication Cyst Presenting as an Inguinal Hernia. *Korean J Pathol* 44: 204-206
8. Bremer JL (1944) Diverticula and duplication of the intestinal tract. *Arch Pathol* 38: 132-140.
9. Álvarez-Solís RM, Chagolla-Santillan FJ, Quero-Hernández A, Leonardo-Puerta JD, Bulnes-Mendizábal D, et al. (2007) Duplicación gástrica asociada a quiste pancreático congénito. Descripción de un caso. *Salud en Tabasco* 13: 663-667.
10. Liaqat N, Latif T, Khan FA, Iqbal A, Nayyar SI, Dar SH (2014) Enteric duplication in children: A case series. *Afr J Paediatr Surg* 11: 211-214.
11. Sheikh MA, Latif T, Shah MA, Hashim I, Akhtar J (2010) Ileal duplication cyst causing recurrent abdominal pain and melena. *APSP J Case Rep* 1: 4
12. Zúñiga-R. S, Skorin-B I, Gejman-E R (2010) Duplicación esofágica. Caso clínico. *Rev Chil Cir* 62: 395-398.
13. Berrocal T, Hidalgo P, Gutiérrez J, de Pablo L, Rodríguez-Lemos R (2004) Imagen radiológica de las duplicaciones del tubo digestivo. *Radiología* 46 :282-292.
14. Briceño J, Briceño M, González D, Sanabria A, González I, Reymundez M, Motta F. Duplicaciones entéricas en pediatría. *Rev Soc Ven Gastro* 2010, 64 (4): 311-315.
15. Zahir I, Yusuf S, Zada F, Asif M, Akhtar N, et al. (2010) Duplication Cyst in a New Born. *International Journal of Pathology* 8: 84-86.
16. Castro-Castañeda S, Chávez-Delgado ME, Cerda-Camacho F (2005) Hemorragia intestinal severa en una niña con duplicación ileal y breve reseña de la entidad. *Cir Pediatr* 18: 142-147
17. Correia-Pinto J, Tavares, ML, Monteiro J, Moura N, Guimaraes H, Esteveao-Costa J. Prenatal diagnosis of abdominal enteric duplications. *Prenat Diagn* 2000; 20: 163-167.
18. Chubkin I, Voronin DV (2011) Gastric duplication cysts: case report. *Ultrasound in Obstetrics & Gynecology* 38: 168-281.