

## Case Report

### An 18-Year-Old Asthmatic Woman with Pneumomediastinum and Pneumorrhachis

Christiane Aires Teixeira<sup>1</sup>, João Daniel Bringel Rego<sup>1</sup>, Vitorino Modesto dos Santos<sup>2\*</sup>, Ana Carla Andrade de Almeida<sup>1</sup> and Rosane Rodrigues Martins<sup>3</sup>

<sup>1</sup>Pneumology Division of Armed Forces Hospital, Brasília-DF, Brazil

<sup>2</sup>Internal Medicine Department of Armed Forces Hospital, and Catholic University of Brasília, Brasília-DF, Brazil

<sup>3</sup>Radiology Division of Armed Forces Hospital, Brasília-DF, Brazil

\*Corresponding author: Vitorino Modesto dos Santos, Department of Medicine, Armed Forces Hospital (HFA), Estrada do Contorno do Bosque s/n, Cruzeiro Novo, 70630-900, Brasília-DF, Brazil, Tel: 55-61 32330812; Fax: 55-61 32331599; E-mail: [vitorinomodesto@gmail.com](mailto:vitorinomodesto@gmail.com)

Rec date: Feb 22, 2014 Acc date: Oct 9, 2014 Pub date: Oct 13, 2014

#### Abstract

**Introduction:** Pneumorrhachis is the presence of free air in the spinal canal. This rare condition is more often asymptomatic and commonly detected as an incidental image finding. Pneumorrhachis in association with pneumomediastinum and subcutaneous emphysema has been scarcely described. Pneumocephalum and pneumothorax are additional associations. Rare cases of pneumorrhachis associated with neurological symptoms require the adoption of decompression procedures. However, conservative management can lead to spontaneous resolution in the majority of the patients.

**Clinical case:** An 18-year-old Brazilian female presented with subcutaneous emphysema, pneumomediastinum, and pneumorrhachis following an exacerbation of bronchial asthma and cough. The main features were chest pain, breathlessness, hoarsened voice and subcutaneous emphysema. The diagnosis was established with base on the characteristic findings of chest radiography and computed tomography. Her management was conservative and the patient improved in a short time.

**Conclusion:** Clinical features do not do the diagnosis of pneumorrhachis, and this entity may be unrecognized. Case reports might increase the suspicion index of primary care physicians about this rare condition.

**Keywords:** Asthma; Lumbar puncture; Spontaneous pneumomediastinum; Subcutaneous emphysema; Pneumorrhachis

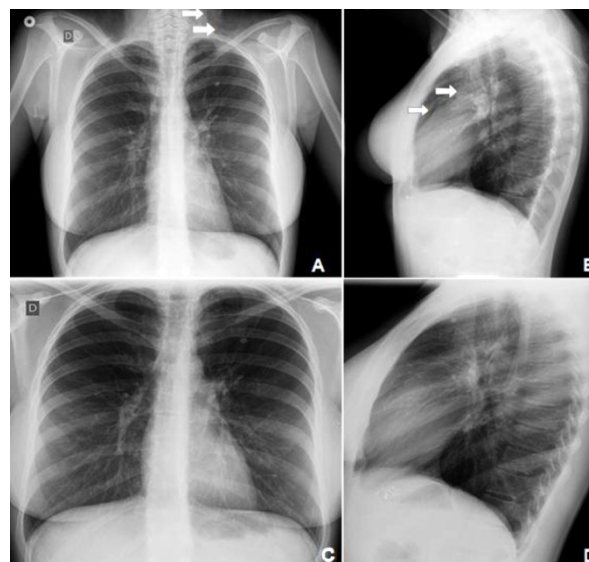
#### Introduction

Pneumomediastinum is the presence of free air in the mediastinal space, condition more often found in neonates, and predominant in males (8:1) and in 1% of asthmatics. The main clinical features are chest pain and dyspnea, but are frequently diagnosed with based on the images [1-5]. Pneumorrhachis is the presence of free air in the spinal canal, a scarcely reported condition that follows pneumocephalus, or is detected as an incidental finding of imaging

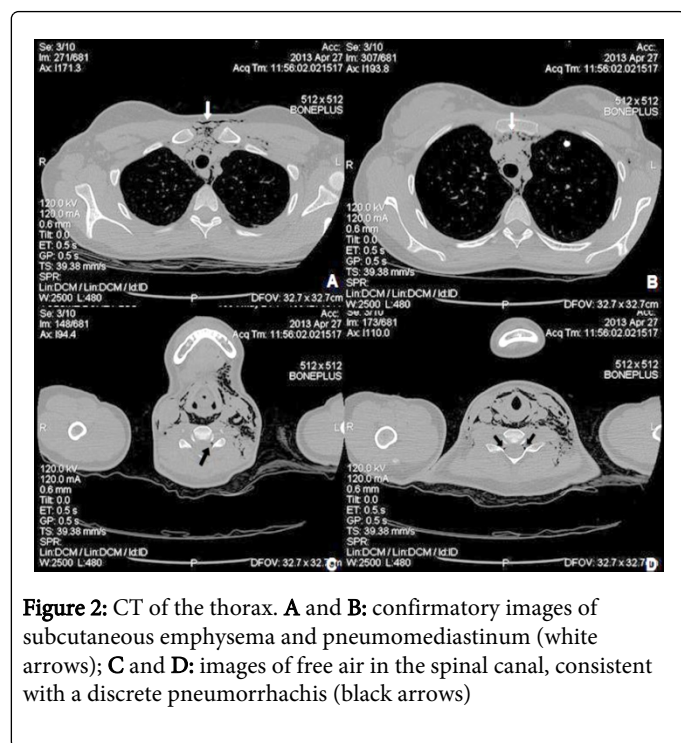
studies [6-10]. Pneumorrhachis is usually asymptomatic, and diagnosis is based on confirmatory images [6-10]. The rare coexistence of pneumomediastinum, subcutaneous emphysema and pneumorrhachis, is herein described during an exacerbation of bronchial asthma in a young Brazilian female.

#### Case Report

An 18-year-old Brazilian woman came to the Emergency Unit with dyspnea, non-productive cough, chest wheezing, and neck pain that had initiated four days before. On the day before her admission, there was worsening of dyspnea, fever (39°C), odynophagia, hoarseness, and a progressive enhancement in the volume of the neck. Physical examination revealed mild subcutaneous emphysema involving the neck region as well as the upper third of thoracic surface, and diffuse chest wheezing. Respiratory rate was 22/min, with an oxygen saturation of 93% in the ambient air. She was asthmatic since infancy and had a cesarean labor four months before admission. Chest x-ray showed pneumomediastinum and subcutaneous emphysema, and these changes were confirmed by the computed tomography (CT) images, that disclosed the concomitant presence of a discrete pneumorrhachis (Figures 1 and 2). Laboratory routine results were normal. She was admitted to the Pneumology ward, and evolved with fast regression of the subcutaneous emphysema, and respiratory improvement. Conservative management included bed rest, analgesia, corticosteroids and O<sub>2</sub> inhalations. She was discharged asymptomatic to the outpatient surveillance on Day 5 after admission.



**Figure 1:** Chest X-ray. **A:** subcutaneous emphysema on the neck and on the left supraclavicular fossa (arrows); **B:** classical images of pneumomediastinum (arrows); **C and D:** normal images of control, with absence of free air in the tissues



**Figure 2:** CT of the thorax. **A** and **B:** confirmatory images of subcutaneous emphysema and pneumomediastinum (white arrows); **C** and **D:** images of free air in the spinal canal, consistent with a discrete pneumorrhachis (black arrows)

## Discussion

The hypothesis of pneumomediastinum was raised in this patient with thoracic pain and subcutaneous emphysema, but the diagnosis of pneumorrhachis was incidentally done. Clinical features of pneumomediastinum depend upon the volume of free air in that space, and main symptoms are chest pain, dyspnea, hoarseness of voice and subcutaneous emphysema [1]. Pain and dyspnea occur in 70%, and the Hamman sign in less than 50% of the patients [1]; this sign is a crunching, rasping sound caused by the heart beating against air-filled tissues. Pneumothorax, including the hypertensive type, may be secondary to pneumomediastinum [1]. Factors related to pneumomediastinum include airway obstruction (asthma, glottic spasm, tumor), mechanical ventilation, vomiting, Valsalva maneuver, drug inhalation, chest trauma, iatrogenic, and free air passed from structures of the chest or abdomen [1]. Non-traumatic pneumomediastinum occurs in asthmatic patients due to tears of alveoli or of pleural blebs, occasionally associated with episodes of forceful persistent cough as herein described [3-5]. Aerorachia, epidural emphysema, pneumocele, pneumosaccus, spinal epidural or subarachnoid pneumatosis, and pneumomyelogram are all synonymous of pneumorrhachis [6]. Pneumorrhachis may be classified as primary or secondary; and internal (intradural, subdural and subarachnoidal) or external (extradural, intraspinal and epidural), with different causal factors and variable pathogenic mechanisms to explain the entry of the air into the spinal canal [3]. The epidural modality may be iatrogenic (epidural anesthesia), non-traumatic or traumatic [3]. The etiologic factors of pneumorrhachis include abscess, bowel perforation, bronchial asthma, endoscopic epidural/spinal injection trauma/surgery on the head or spinal bones, pneumocephalus, pneumomediastinum, pneumothorax, subcutaneous emphysema, synovial cyst, and vacuum disk, among others [6-10]. Epidural pneumorrhachis was described in asthmatic patients with violent/persistent cough [9]. Firstly, increased intra-alveolar pressure

due to forceful cough causes alveolar rupture, and free air leaking in the peribronchial and mediastinal spaces produces pneumomediastinum [3,7]. The air travels by facial planes from the mediastinum to the neck and the epidural space [3,4,9,10]. The mechanisms of pneumorrhachis in the present case study might include the passage of free air from the posterior mediastinum to neural foramina and to epidural spaces, in addition to the direct air injection during the procedures of her previous epidural anesthesia [7-10].

## Conclusion

Pneumorrhachis is a rare and often asymptomatic condition, which has been frequently controlled on an individual basis because of the lack of respective consensual guidelines [3,6]. The diagnosis is not clinically done, and is exclusively dependent upon the imaging studies. The asthmatic patient herein reported was managed with success by non-invasive procedures, and the antibiotics were administered aiming to prevent eventual infectious complications. Case reports might increase the suspicion index of primary care physicians about this rare disorder.

## Acknowledgements

The authors would like to thank Almir José Batista, the official photographer of the Armed Forces Hospital, in Brasília-DF, Brazil for the images that illustrate the present case study.

## References

1. Cunha Fatureto M, Vieira dos Santos JP, Nunes Goulart PE, Andrade Maia S (2008) [Spontaneous pneumomediastinum: asthma]. *Rev Port Pneumol* 14: 437-441.
2. Kono T, Kuwashima S, Fujioka M, Kobayashi C, Koike K, et al. (2007) Epidural air associated with spontaneous pneumomediastinum in children: uncommon complication? *Pediatr Int* 49: 923-927.
3. Patel V, Raval G, Gavadia K (2012) Pneumothorax, pneumomediastinum, subcutaneous emphysema and pneumorrhachis as complications of common flu. *Am J Case Rep* 13: 198-201.
4. Ryoo JY (2012) Clinical analysis of spontaneous pneumomediastinum. *Tuberc Respir Dis (Seoul)* 73: 169-173.
5. van der Klooster JM, Grootendorst AF, Ophof PJ, Brouwers JW (1998) Pneumomediastinum: an unusual complication of bronchial asthma in a young man. *Neth J Med* 52: 150-154.
6. Arora S, Aggarwal P, Cheema GS, Singla J (2011) Pneumorrhachis of the cervical spine with associated pneumocephalus and subcutaneous emphysema. *Indian J Orthop* 45: 372-375.
7. Botchu R, Shah A, Burli P (2012) Epidural emphysema following blunt trauma: a case report and review of literature. *Iowa Orthop J* 32: 224-226.
8. Chaichana KL, Pradilla G, Witham TF, Gokaslan ZL, Bydon A (2010) The clinical significance of pneumorrhachis: a case report and review of the literature. *J Trauma* 68: 736-744.
9. Karaoglan A, Cal MA, Orki A, Arpaou BM, Colak A (2011) Pneumorrhachis associated with bronchial asthma, subcutaneous emphysema and pneumomediastinum. *Turk Neurosurg* 21: 666-668.

10. Song Y, Tu L, Wu J (2009) Pneumorrhachis with spontaneous pneumomediastinum and subcutaneous emphysema. *Intern Med* 48: 1713-1714.