



Research Article

The Combined Use of Intracaval and Oral Calcium for the Treatment of Hereditary Vitamin D Resistant Rickets (HVDRR)

Abdulmoein E. Al-Agha^{1*} and Ihab A. Ahmad²

¹Department of Pediatrics (Al-Agha, Ahmad), King Abdulaziz University Hospital, Jeddah, Kingdom of Saudi Arabia

²Department of Pediatrics (Ahmad), Faculty of Medicine, Zagazig University, Zagazig, Egypt

*Corresponding author: Dr. Abdulmoein Eid Al-Agha, Department of pediatrics, Faculty of Medicine, King Abdulaziz University, Jeddah, Saudi Arabia; Tel: 0505590459; E-mail: aagha@kau.edu.sa

Rec date: April 10, 2014 Acc date: Aug 01, 2014 Pub date: Aug 04, 2014

Abstract

Introduction: Hereditary vitamin D resistant rickets (HVDRR), also known as vitamin D-dependent rickets type II, is an autosomal recessive disorder characterized by the early onset of rickets with hypocalcemia, secondary hyperparathyroidism and hypophosphatemia.

Objectives: To study the success of our designed protocol of continuous high dose intracaval, oral calcium and phosphate for the treatment of HVDRR.

Patients and methods: We studied seven patients (four males and three females) with HVDRR, Four of them with alopecia. Age of starting treatment ranged from 1.2 -7 years. Daily infusions ranging from 1-2.2 g elemental calcium supplemented with oral phosphate ranged from 1-2 g and calcium ranged from 3.2-4.2 g elemental calcium were given for a period of 8-12 months. Followed by maintenance on oral calcium equivalent to 6.2 - 8g elemental calcium per day with oral phosphate 1-2 g.

Measurements of serum calcium, phosphate and serum alkaline phosphatase were obtained before, during and after the calcium infusions. Urea and electrolytes, serum parathyroid hormone and vitamin D metabolites were measured prior to calcium infusion, then repeated at monthly intervals. Kidney ultrasound was done at 6-monthly intervals. X-ray before and 6 and 12 months after treatment was done.

Results: The daily intracaval infusions of calcium supplemented with oral phosphate and calcium resulted in clinical and biochemical and radiological responses with normalization of calcium and phosphate, alkaline phosphatase and parathyroid hormone in 8-12 months with improvement in height slandered deviation. The patients showed no evidence of nephrocalcinosis on follow up

Conclusion: The use of intracaval calcium infusions followed by high dose oral calcium with oral phosphate is an effective method of treatment of HVDRR.

Keywords: Rickets; Hereditary vitamin D resistance rickets; 1, 25-Dihydroxy vitamin D

Introduction

The term 'vitamin D resistant rickets' was first used in 1937 by Albright et al. who described a form of rickets requiring large doses of vitamin D for healing of nutritionally deficient rickets [1]. HVDRR is a rare form of autosomal recessive disorder often caused by mutation on vitamin D receptor gene preventing normal physiological response to 1,25(OH)₂ vitamin D. Levels of 1,25(OH)₂D are elevated and constitute the hallmark diagnostic laboratory test[2]. The disease presents with a clinical picture of rickets, hypocalcemia, hypophosphatemia, growth retardation, secondary hyperparathyroidism along with elevated circulating levels of 1,25(OH)₂D [3]. In lack of facilities for estimation of 1, 25(OH)₂D and parathyroid hormone, alopecia remains the only clue to the diagnosis of this rare syndrome in association with resistant rickets [4].

Patients and methods

We retrospectively reviewed a cohort of 7 children with HVDRR presenting to King Abdulaziz University Hospital, Jeddah, Kingdom of Saudi Arabia in four years duration. All patients were referred to our center due to failure of response to conventional therapy of vitamin D. Local ethical approval was obtained, and the study was conducted according to the principles of the Helsinki Declaration.

Diagnostic criteria

The diagnosis of HVDRR was made by history of failure of response to vitamin D and oral calcium, clinical findings of rickets and biochemical evidence of hypocalcemia, secondary hyperparathyroidism, hypophosphatemia and elevated alkaline phosphatase (ALP).

All patients had anthropometric measurements (height, weight, head circumference), serum calcium, phosphorus, alkaline phosphatase, electrolyte and magnesium before and weekly during period of treatment while parathyroid hormone (PTH) was done before and monthly during period of treatment and 25(OH) vit D , 1,25(OH)₂D was done for diagnosis.

X-ray was done before and 6 months after treatment and then accordingly till healed rickets confirmed.

All patients underwent Porta-a-cath insertion before starting treatment and needles were changed weekly and heparin saline was infused twice daily to prevent obstruction of the catheter.

Our protocol consisted of:

Daily infusion of calcium gluconate (1- 2.2 g elemental calcium) plus either sodium or potassium phosphate (200-1200 mg) with oral calcium (3.2-4.2 g elemental calcium)

These medications used until complete healing clinically, biochemically and radiologically. Then central line removed and patients continued on high doses of oral calcium and phosphate

Follow up of weekly bone function profile and monthly parathyroid hormone

After complete healing, daily oral calcium (6.2–8g elemental calcium) and phosphate (1–2 g)

Patients who failed to catch up height SDS, growth hormone started

Results

The patients were treated by intracaval infusions of calcium through a Porta -a -cath. A total of two (1- 2.2 g elemental calcium) was infused daily for 8-12 months and the serum calcium concentration was maintained at 2.12-2.51mmol/l. Bone pain subsided within two weeks of treatment. Serum phosphorus, parathyroid hormone concentrations and alkaline phosphatase activity were normalized within 6 months (Table 2). Radiographs of the hands revealed progressive healing of rickets with complete resolution after 8-12 months of treatment (Figure 1). The patients gained average of 9-11 cm per year in height as compared with 3 cm before treatment (Table 1).

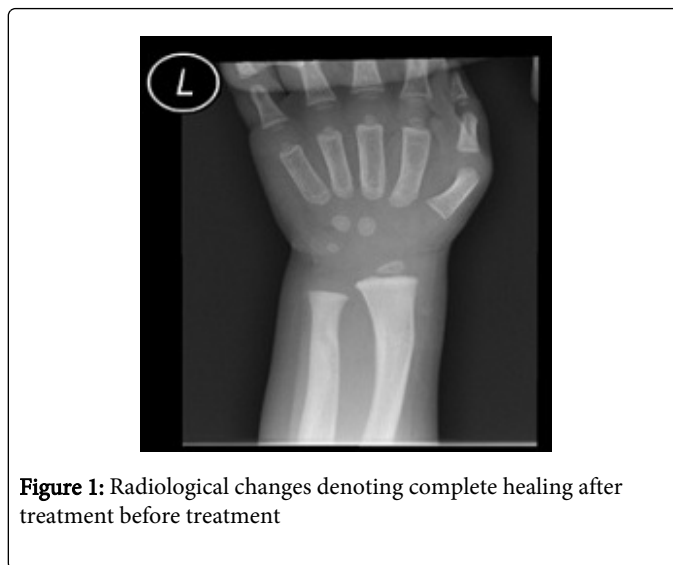


Figure 1: Radiological changes denoting complete healing after treatment before treatment

	Patient 1		Patient 2		Patient 3		Patient 4		Patient 5		Patient 6		Patient 7	
Gender	Male		Male		Male		female		Male		female		Female	
Age of starting treatment	3 years		2.2 years		1.9 years		7 years		1.2 years		4 years		1.6 years	
Duration of treatment	1 year		1 year		1 year		8 months		1 year		8 months		1 year	
Consanguinity	Yes		Yes		Yes		No		Yes		No		Yes	
Alopecia	Yes		Yes		No		No		No		Yes		Yes	
	*	**	*	**	*	**	*	**	*	**	*	**	*	**
Height cms	85	96	79	90	75	87	105	115	72	84	89	100	73	85
Height SDS	< -2.25	-1.5	< -2.25	-1.5	< -2.25	-1.5	< -2.25	-2.25	< -2.25	-1.28	< -2.25	-1.5	< -2.25	-1.28

Table 1: Demographic data of patients' * before treatment ** after treatment

	Ca 2.12-2.52 mmol/L		Phos. 0.8-1.5 mmol/L		ALP 50-200 U/L		PTH 1.6-6.9 Pmol/L	Oral calcium		Iv calcium		Oral phosphate
Patient 1	*	**	*	**	*	**	*	**	*	**		
	1.7	2.4	0.7	1.1	1250	220	25	5.2	3.2g	6.2g	1g	1.5g
Patient 2	1.8	2.5	0.6	1.3	1050	210	17	2.3	3.5g	8g	1.8g	2g
Patient 3	1.4	2.3	0.7	1.4	1650	178	26	4.3	4g	7.7g	2.1g	1.5
Patient 4	1.9	2.4	1.1	1.2	1370	156	19	3.6	3.3g	6.8g	1.9g	1g
Patient 5	1.8	2.4	0.6	1.1	1075	240	15	4.1	3.6g	8 g	2.2g	1.5g
Patient 6	.1.9	2.5	0.8	1.3	1360	190	23	3.7	4.2g	7.1g	1.6g	1g
Patient 7	2.00	2.35	0.7	1.4	1540	230	27	2.5	4.1g	6.7g	2.2g	1g

Table 2: Biochemical data, intracaval, oral calcium and oral phosphate doses dose in elemental calcium * before treatment ** after treatment

Discussion

We used the term HVDRR instead of vitamin D-dependent rickets type II as this is misname as dependent means depend on treatment but resistance means defect in receptor.

Vit D-resistant rickets is a rare disorder characterized by resistance to therapeutic regimens and appears in several different phenotypes and clinical features. HVDRR is extremely rare and is mostly accompanied by alopecia. The disease is caused by target organ resistance to $1,25(\text{OH})_2\text{D}$, the biologically active form of Vit D. [5] The diagnosis is made by finding normal or elevated circulating levels of $1,25(\text{OH})_2\text{D}$. [6,7] In our patients $25(\text{OH})\text{Vit D}_3$ was ranging from (normal) ng/mL; and $1,25(\text{OH})_2\text{D}$.

Five of our patients were born out of consanguineous marriage and had clinical, laboratory and radiological findings compatible with HVDRR (rachitic rosaries, low calcium, low phosphate, secondary hyperparathyroidism, normal serum $25(\text{OH})\text{vit D}_3$ and high $1,25(\text{OH})_2\text{D}$). These data come in concordance with 21 patients studied by Hochberg. [8] These patients had hypocalcaemia, raised ALP (990-5500U/L), elevated PTH (85-480 pg/ml), normal $25(\text{OH})\text{D}_3$ (14-35ng/ml) and raised $1,25(\text{OH})\text{vit D}$ (95-280 pg/ml).

Most of our patients presented with low phosphate which attributed mainly to phosphaturic effect of secondary hyperparathyroidism. One of our patients diagnosed by screening as his brother was affected by the disease which has a 25% chance of recurrence (AR inheritance).

Growth failure is frequent in HVDRR [9]. Height of our patients were below -2.25 SDS which improved range (-1.5-1.28 SDS) after one year of treatment. Growth failure occurs in the first year of life during which rachitic bone changes like craniotabes, rosary, and wide wrist, bowing of legs, deformities of lower limb bones and X-ray evidence of rickets. [8] Our patients showed most of the above mentioned rachitic features (Figure 2).

HVDRR consists of a spectrum of intracellular vitamin D receptor (VDR) defects and is characterized by the early onset of severe rickets with or without alopecia. The cause of alopecia could be due to the lack of ligand-independent function of the vitamin D receptor in keratinocytes which is necessary for proper anagen initiation [10].

Alopecia can be the only clinical sign at birth. It involves the scalp, body, pubic hair and often eyebrow but spares the eyelashes. [8] Four of our patients had alopecia of the scalp and eye-brow. Severe alopecia is associated with resistance to calcitriol therapy and severe manifestations [5] Dental health is poor in patients with HVDRR with findings of severe caries, enamel hypoplasia, gingivitis and delayed eruption. [8] All our patients had delayed eruption of tooth while 3 patients had other dental caries and enamel hypoplasia.

All patients showed low normal calcium with low phosphorous levels and high alkaline phosphatase levels The levels of $1,25(\text{OH})_2\text{D}$ are elevated which is considered to be the diagnostic hallmark of this disease [2]. HVDRR is resistant to vitamin D treatment and the response to massive doses of $1,25$ -dihydroxyvitamin D is variable.

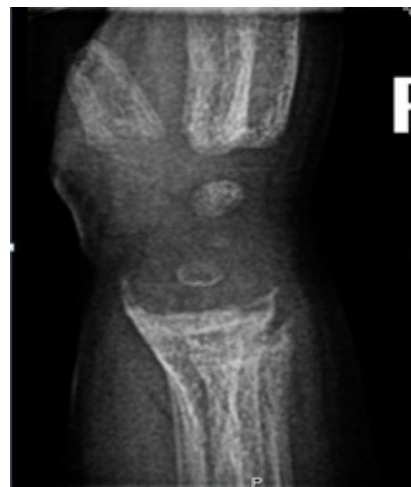

Figure 2: Radiological changes including cupping, fraying, widening of metaphysis, and osteopenia before treatment

Our protocol involves intracaval high doses of calcium gluconate which ranged from 1.0 -2.2 gram elemental calcium daily for period ranged from 8-12 month, intracaval sodium phosphate 1-2 g and oral calcium 3.2-4.2 gram elemental followed by high dose calcium (6.2-8 g elemental calcium) in conjunction with oral phosphate 9.1-2 g).

This come in concordance with alaqeel et al. [11] who studied daily infusions equivalent to up to 1.4g elemental calcium supplemented with oral phosphate given for a period of 3.5 months for one patient and 2 months for another patient. Both patients were then treated by weekly calcium infusions for 5 months, followed by maintenance on oral calcium equivalent to up to 6g elemental calcium per day and resulted in biochemical responses with normalization of calcium and phosphate in 3-5 days, and of alkaline phosphatase and PTH in 1.5-2 months. Evidence of healing radiologically was seen in 42 days with improvement in height.

Weisman et al. [12] studied two boys aged six and four with the syndrome of hereditary resistance to $1,25$ -dihydroxyvitamin D_3 with rickets, alopecia and growth retardation. Patients treated by long-term intracaval infusions of calcium through an implantable catheter. A total of 0.5 to 0.9 g of elemental calcium infused daily for 18 months and the serum calcium concentration was maintained at 9 to 10 mg/dl. Bone pain resolved within one week of treatment. Serum phosphorus, parathyroid hormone, and $1,25$ -dihydroxyvitamin D concentrations and alkaline phosphatase activity were normalized within four to nine months. Radiographs revealed progressive healing of rickets with picture of healed rickets after one year of treatment. The patients gained 12 cm and 8 cm per year in height as compared with 3 cm and 2 cm, respectively, in the previous year.

Conclusion

The use of intracaval high dose calcium infusions followed by high dose oral calcium is an effective method of treatment of HVDRR.

References

1. Albright F, Butler AM, Bloomberg E (1937) Rickets resistant to vitamin D therapy. *AJDC* 54: 529-547.
2. Kliegman RM, Behrman RE, Jenson HB, Stanton BF (2010) *Nelson Textbook of Pediatrics*. 18th Edition Saunders Iceland: Elsevier/Saunders 253–262.
3. Mishra S, Yadav TP, Nangia S, Gupta VK, Sidhu KK (1996) Vitamin D dependent rickets type II. *Indian Pediatrics* 33: 334-336.
4. Malla K, Malla T, Shaw C, Thapalial A (2010) Type II vitamin D dependent rickets: A case report. *Journal of Nepal Paediatric Society* 30: 46-49.
5. Takeda E, Kuroda Y, Saijo T, Naito E, Yokota I, et al. (1987) 1-alpha-hydroxyvitamin D3 treatment of three patients with 1,25-dihydroxyvitaminD3 receptor defect rickets and alopecia. *Pediatrics* 80: 97–101.
6. Griffin JF, Zerwekh JE (1983) Impaired stimulation of 25-hydroxyvitamin D-24 hydroxylase in fibroblasts from a patient with vitamin D-dependent rickets type II. A form of receptor-positive resistance to 1,25-dihydroxyvitamin D3. *J Clin Invest* 72: 1190 – 1199.
7. Beer S, Tieder M, Kohelet D, Liberman OA, Vure E, et al. (1981) Vitamin D-resistant rickets with alopecia: a form of end-organ resistance to 1,25-dihydroxyvitamin D3. *Clin Endocrinol* 14: 395–402.
8. Hochberg Z (2002) Vitamin-D-dependent rickets type 2. *Horm Res* 58: 297-302.
9. Kruse K, Feldmann E (1995) Healing of rickets during vitamin D therapy despite defective vitamin D receptors in two siblings with vitamin Ddependent rickets type II. *J Pediatr* 126: 145-148.
10. Sakai Y, Kishimoto J, Demay MB (2001) Metabolic and cellular analysis of alopecia in vitamin D receptor knockout mice. *Journal of Clinical Investigation* 107: 961-966.
11. Al-Aqueel A, Ozanel P, Sobki S, Sevairi W, Marx S (1993) The combined use of intravenous and oral calcium for the treatment of vitamin Ddependent rickets type II (VDDR II). *Clin Endocrinol (Oxf)* 39: 229-2237.
12. Weisman Y, Bab I, Gazit D, Spirer Z, Jaffe M et al. (1987) Long-term intracaval calcium infusion therapy in end-organ resistance to 1,25-dihydroxyvitamin D *Am J Med* 83: 984-990.