

## Research Article

# Large Buruliulcer of Right Arm Complicated by Radial Nerve Palsy Treated with Latissimus Dorsi Flap and Triple Tendon Transfer

Kibadi Kapay Anatole<sup>1\*</sup>

### Abstract

The author reports a case of a large Buruliulcer (*Mycobacterium ulcerans* infection) of right arm complicated by radial nerve palsy. *Mycobacterium ulcerans* infection was treated with antibiotics (Rifampicin and Streptomycin) for 8 weeks, as recommended by the World Health Organization. For large Buruliulcer, necrotic tissue after cleaning, *Latissimus dorsi flap* was performed. Radial nerve palsy was treated by a triple tendon transfer. The transfer of *pronator teres* to *extensor carpi radialis brevis*, *flexor carpi ulnaris* to *extensor digitorum communis* and *Palmaris longus* to *extensor pollicis longus* has been made to restore the function of the extension of the wrist, fingers and thumb. Immobilization and rehabilitation framed surgery. The patient recovered the different functions of member repaired. After follow-up of three years, no complications (bone or skin) were observed.

This work shows that despite the limited resources that may have medical and surgical in which the working environment, it is possible to obtain a good therapeutic outcome, even to complicated or hopeless cases, if the basic principles of medical and surgical treatment (plastic surgery) are respected. Indeed, this member could also benefit from amputation..

### Keywords

Buruliulcer; Radial nerve palsy; Treatment; *Latissimus dorsi flap*; Tendon transfer; Working environment with limited resources; Democratic republic of congo

### Introduction

*Mycobacterium ulcerans* infection, commonly called “Buruliulcer” (BU) causes skin lesions, necrotic ulcerative [1]. Three stages of the disease are recognized: non-ulcerative stage (nodule, edema, plaque, and papule), the ulcerative stage and scar stage. With bone, neurovascular are also observed [1]. The World Health Organization (WHO) recommends treatment by specific antibiotics (Rifampin and Streptomycin) for 8 weeks. Surgery, if necessary, can intervene at the end of the 4th week of specific antibiotics [2].

\*Corresponding author: Kibadi Kapay Anatole, Head of Unit of Plastic, Reconstructive & Aesthetic Surgery, Surgery of Hand and Burns University, Hospital of Kinshasa, Faculty of Medicine, University of Kinshasa, Democratic Republic of Congo, Tel: 00243817212310; E-mail: akibadi@yahoo.fr

Received: May 12, 2014 Accepted: October 13, 2014 Published: March 15, 2015

Many surgeons have reported their experiences in the management of sequelae of BU; in a humanitarian mission in Benin [3], in the practice of plastic surgery in Ivory-Cost [4] and in the Democratic Republic of Congo (DRC) [5]. Tendon transfer in the palliative treatment of radial nerve palsy is old more than a century. All tendon that could be considered useful, could be used for this purpose [6].

This study presents a complicated and hopeless BU case with radial nerve palsy treated by specific antibiotics and reconstructive surgery in a medical and surgical environment with resources limited.

### Observation

Patient (34 years old) consulted us for a large ulcer with necrotic tissues of right arm exposing the humerus (Figure 1) and we observed also radial nerve palsy (Figure 2). Disease duration was more than two years in the Republic of Angola, where the patient was probably infected around Kafufu /Luremo (city).

The place of contamination would be the new focus of BU that was recently discovered along the Cuango / Kwango River between the Republic of Angola and the DRC [7]. The initial form of the disease was a nodule that had evolved into a large ulcer. Despite a prescribed and taken by the patient in Angola chemotherapy, the disease worsened, pattern transfer in the DRC for better management Upon arrival in our Unit of Plastic Surgery of University Hospital of

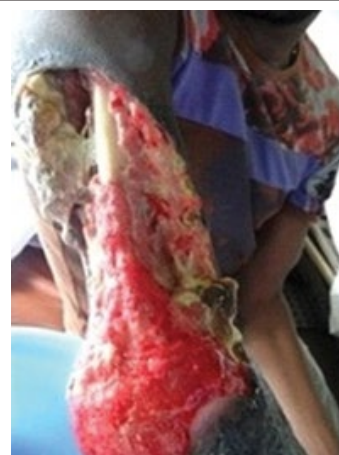

Figure 1: Large BU of arm (before surgery).

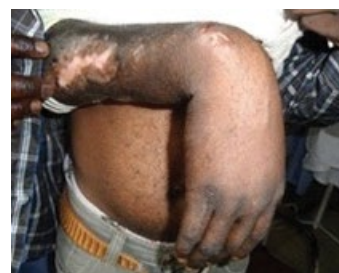

Figure 2: Radial nerve palsy (before surgery).

Kinshasa (DRC), the diagnosis of *Mycobacterium ulcerans* infection was performed on the basis of clinical and epidemiological elements, as well as on the basis of positive microbiological analyzes from biopsies: Polymerase reaction Chain (PCR), direct microscopy by Ziehl -Neelsen(ZN) .

The patient treated by Rifampicin - Streptomycin for 8 weeks. Surgery started after 4 weeks of specific antibiotics in accordance with WHO recommendations [2]. We performed the dressings of necrotic tissue (Figure 3) with local care by aqueous solution of Chloramine - Metronidazole - Nitrofurandoïne called « solution Kibadi » in RDC [8]. For the significant loss of soft tissue of the arm, we performed *Latissimus dorsi flap* (Figures 4 and 5) that we have weaned after 3 weeks (Figure 6). For radial nerve palsy (Figure 2), we performed a triple tendon transfer to revive the wrist, fingers and thumb.

To restore the function of wrist extension, we transferred pronatorteres to *extensor carpi radialis brevis* (Figures 7-9). We restored the function of the extension of the fingers by transfer *flexor carpi ulnaris* to *extensor digitorum communis* (Figures 10-12). And, we restored the function of the extension of the thumb by transfer *Palmaris longus* to *extensor pollicis longus* (Figures 13 and Figure 14).

Immobilization for three weeks followed by rehabilitation was performed after surgery. The patient recovered the different functions of member repaired. After follow-up of three years, no complications

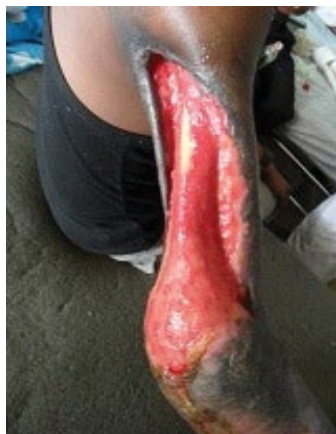

Figure 3: Large BU (after cleaning).

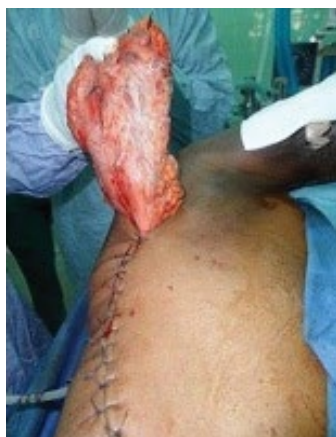

Figure 4: Latissimus dorsi flap.

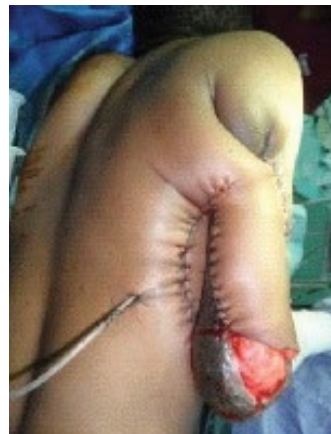

Figure 5: Latissimus dorsi flap in arm.

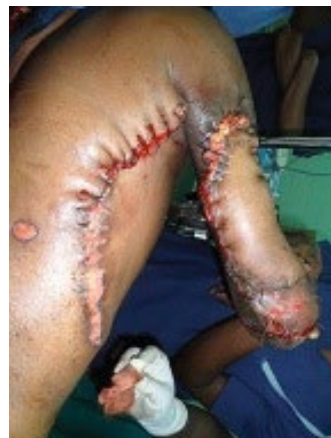

Figure 6: Weaning flap (3 weeks after).

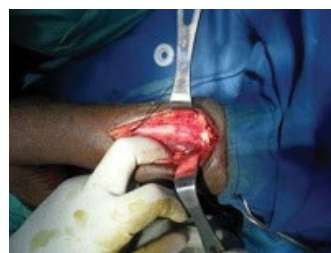

Figure 7: Pronatorteres.

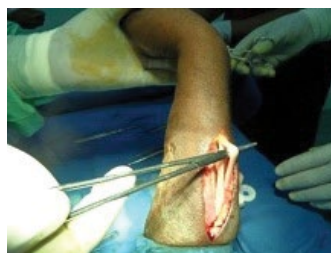

Figure 8: Extensor carpi radialis brevis.

(bone or skin) were observed. We observed excellent flexion and extension of elbow, wrist, fingers and thumb (Figure 15).

### Discussion

The option of an amputation could be adapted to the extent of the lesions (Figure 1 and Figure 2), but we opted for reconstructive surgery, despite this medical and surgical environment with resources limited where we worked. Indeed, there is no health insurance in the country. The population is poor. The patient paid the costs of surgery and hospitalization, also it was difficult to work in optimal conditions required such reconstructive surgery. But, we respected the basic principles of medical and surgical treatment (plastic surgery) for management of this patient.

The flap of *latissimus dorsi* is universal flap in plastic surgery and it opens up many possibilities for repair as illustrated by this very complex case sequelae of BU [9]. As for the treatment of radial nerve palsy, we opted for a triple tendon transfer according to Merle d'Aubigné technical [10], with fireworks Tubiana [11]. This technique is simple and reliable implementation, easily reproducible. If radial palsy, paralysis of wrist extension alone lost two thirds of the normal gripping force of the hand. The best engine to use *pronator teres* is the priority. Several therapeutic options is considered. Indeed, Tubiana, Smith and Boyes to restore wrist extension, they transfer all

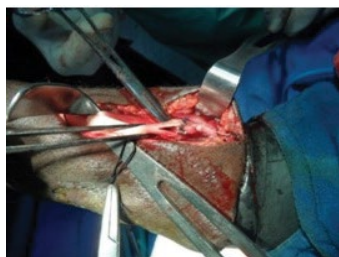

Figure 9: Transfer of pronator teres.

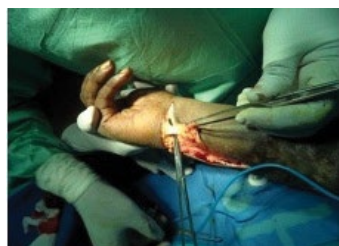

Figure 10: Flexor carpi ulnaris to extensor carpi radialis brevis.

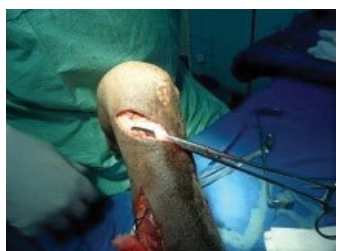


Figure 11: Extensor digitorum communis.

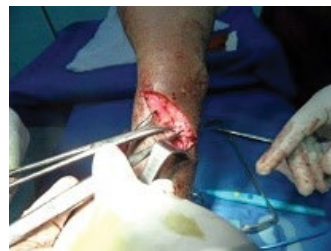

Figure 12: Transfer of flexor carpi ulnaris to extensor digitorum communis.

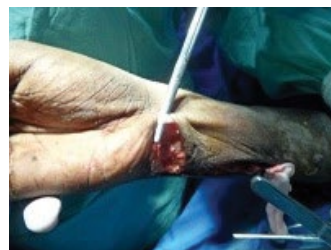

Figure 13: Palmaris longus to extensor pollicis longus.

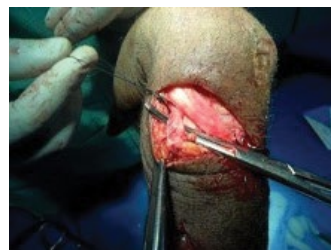

Figure 14: Transfer of Palmaris longus.

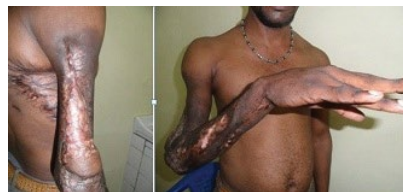

Figure 15: Result after surgery with follow-up of three years: excellent flexion and extension of elbow, wrist, fingers and thumb.

*pronator teres* to *extensor carpi radialis brevis*. But they differ for the restoration of the extension of the fingers and thumb [11].

A study comparing different methods of tendon transfer for radial nerve palsy showed no statistically significant difference in terms of results [12]. In this study, *pronator teres* was transferred for wrist extension. The *flexor carpi ulnaris*, *flexor carpi radialis*, *flexor digitorum superficialis* were used to resuscitate finger extension. The *longus palmaris* was used to resuscitate the extension of the thumb. All patients had experienced functional improvement and overall satisfaction rate was 95%. No complications directly attributable to the operation were noted. These authors [12] conclude that tendon transfer for radial nerve palsy is a surgical procedure usually very successful and that success would probably not be attached only to

the type of transferred tendons. However, we believe that this study [12] has some limitations and the conclusion may be qualified to the extent that it is not a randomized study, but a retrospective study.

Our patient recovered the different functions of member repaired. After follow-up of three years, no complications (bone or skin) were observed. Tendon transfers are among the most successful surgeries in the upper limb [12]. A literature review confirms the very good results with these operations tendon transfers in radial palsy [13-18], and this in accordance with the good results obtained in our patient (Figures 15 and Figure 16).

## Conclusion

*Mycobacterium ulcerans* infection (BU) remains a devastating disease. This work shows that despite the limited resources that may have medical and surgical in which the working environment, it is possible to obtain a good therapeutic outcome, even to complicated or hopeless cases, if the basic principles of medical and surgical treatment (plastic surgery) are respected. Indeed, for our patient, this member could also benefit from amputation.

## Acknowledgement

We thank the staff of the department of surgery (University Hospital of Kinshasa) and the patient for their collaboration. Our thanks also go to Professor NKAKUDULU and his team for the excellent work of rehabilitation.

## References

1. World Health Organization (2000) Buruli ulcer. *Mycobacterium ulcerans* infection. Asiedu K, Scherpier R, Raviglione M WHO Geneva 118.
2. World Health Organization Provisional guidance on the role of specific antibiotics in the management of *Mycobacterium ulcerans* disease (Buruli ulcer). World Health Organization WHO/CDS/CPE/GBUI/2004.10 Geneva.
3. Knipper P, Zilliox R, Johnson C, Antoine P (2004) [Buruli disease and plastic surgery]. *Ann Chir Plast Esthet* 49: 265-272.
4. Ouattara D, Meningaud JP, Kaba L, Sica A, Asse H (2003) [Plastic surgery treatment of Buruli ulcer sequelae. A retrospective study of 16 patients]. *Ann Chir Plast Esthet* 48: 13-19.
5. Kibadi K (2005) *Mycobacterium ulcerans* disease (Buruli ulcer): surgical treatment of 102 cases in the Democratic Republic of Congo. *Med Trop (Mars)* 65: 444-448.
6. Green DP (2003) Radial nerve palsy. In: Green DP, Hotchkiss RN, Pederson WC, Wolfe SW Green's operative hand surgery. 4th edn Philadelphia Pennsylvania: Churchill Livingstone 1113-1130.
7. Kibadi K, Panda M, Tamfum JJ, Fraga AG, Longatto Filho A, et al. (2008) New foci of Buruli ulcer, Angola and Democratic Republic of Congo. *Emerg Infect Dis* 14: 1790-1792.
8. Kibadi K, Tsakala TM, Mputu-Yamba JB, Kashongwe M, Muyembe T (2002) Imposo DB. Essai thérapeutique de l'association chloramines-métronidazole-nitrofurandoïne dans le traitement local de l'ulcère de Buruli surinfecté. *Méd d'Afr Noire* 49 : 239-243
9. Revol M, Binder JP, Danino A, May P, Servant JM (2009) Manuel de chirurgie plastique, reconstructive et esthétique. In: Sauramps médical 2ème édition, révisée et augmentée 84-88.
10. Merle d'Aubigné R, Lance P (1946) Transplantations tendineuses dans le traitement des paralysies radiales post-traumatiques. *Sem Hôp Paris* 22: 1666-1680.
11. Merle M, Dautel G (1995) La main traumatique 2 - chirurgie secondaire & poignet. Edition: Masson, Paris 188-193.
12. Moussavi AA, Saied A, Karbalaiekhani A (2011) Outcome of tendon transfer for radial nerve paralysis: Comparison of three methods. *Indian J Orthop* 45: 558-562.
13. Ropars M, Dréano T, Siret P, Belot N, Langlais F (2006) Long-term results of tendon transfers in radial and posterior interosseous nerve paralysis. *J Hand Surg Br* 31: 502-506.
14. Raskin KB, Wilgis EF (1995) Flexor carpi ulnaris transfer for radial nerve palsy: functional testing of long-term results. *J Hand Surg Am* 20: 737-742.
15. Kruff S, von Heimburg D, Reill P (1997) Treatment of irreversible lesion of the radial nerve by tendon transfer: indication and long-term results of the Merle d'Aubigné procedure. *Plast Reconstr Surg* 100: 610-616.
16. Altintas AA, Altintas MA, Gazyakan E, Gohla T, Germann G, et al. (2009) Long-term results and the Disabilities of the Arm, Shoulder, and Hand score analysis after modified Brooks and D'Aubigne tendon transfer for radial nerve palsy. *J Hand Surg Am* 34: 474-478.
17. Skoll PJ, Hudson DA, de Jager W, Singer M (2000) Long-term results of tendon transfers for radial nerve palsy in patients with limited rehabilitation. *Ann Plast Surg* 45: 122-126.
18. Gousheh J, Arasteh E (2006) Transfer of a single flexor carpi ulnaris tendon for treatment of radial nerve palsy. *J Hand Surg Br* 31: 542-546.

## Author Affiliations

Top

<sup>1</sup>Head of Unit of Plastic, Reconstructive & Aesthetic Surgery, Surgery of Hand and Burns University, Hospital of Kinshasa, Faculty of Medicine, University of Kinshasa, Democratic Republic of Congo