La Prensa Medica Argentina

Research Article

Therapeutic Options in Hypertrophic Cardiomyopathy

Lothar Faber*

Department of Cardiology, Heart and Diabetes Centre North Rhine – Westphalia, Ruhr – University Bochum Georgstrasse 11, D - 32545 Bad Oeynhausen, Germany

***Corresponding author:** Department of Cardiology, Heart and Diabetes Centre North Rhine – Westphalia, Ruhr – University Bochum, Georgstrasse 11, D - 32545 Bad Oeynhausen, Germany, Tel: +49-5731-97 1258; Fax: +49-5731-97-2194; E-mail: lfaber@hdz-nrw.de

Rec date: July 07, 2014**Acc date:** Jan 15, 2015 **Pub date:** Jan 21, 2015

Abstract

Hypertrophic cardiomyopathy (HCM) is one of the more common hereditary cardiac conditions. Several hundreds of mutations in genes coding for sarcomeric or energy metabolism proteins have been found to be associated with the phenotype. Myocardial disarray and fibrosis are the prominent histological findings of the disease. A more common (70%) obstructive (HOCM) has to be distinguished from the less common (30%) non-obstructive phenotype (HNCM). Symptoms include exercise limitation due to dyspnea or angina pectoris, palpitations, or dizziness. Occasionally syncope or sudden cardiac death occurs. Correct diagnosis and risk stratification with respect to prophylactic ICD implantation are essential issues of patient management. Drug therapy in symptomatic patients can be characterized as treatment of heart failure with preserved ejection fraction (HFpEF) in HNCM, while symptoms and the obstructive gradient in HOCM can be addressed with beta-blocking agents or Verapamil. For drug-refractory HOCM, surgical myectomy and percutaneous septal ablation are standard therapies today. The following review summarizes recent developments the management of patients with HCM.

Keywords: Hypertrophic obstructive cardiomyopathy; Percutaneous septal ablation, Myectomy, Risk stratification, Sudden cardiac death, ICD, HOCM, HCM, HNCM

Definition, epidemiology, and pathogenesis

One of the first descriptions of what is nowadays labeled as hypertrophic cardiomyopathy (HCM, 1-62) was written in 1958 by the british pathologist Teare who suspected a cardiac neoplasia [1]. The prevalence of the disease is estimated to be about one case per 500–1000 in the general population worldwide. HCM is characterized by excessive thickening of the left ventricular myocardium, occasionally also involving the right ventricle, without an identifiable cause such as arterial hypertension (Figure 1). Two phenoypes should be distinguished: a more common, obstructive type (HOCM, 70%, Figure 2) in which there is dynamic left ventricular outflow obstruction [2,3,7-10,13,15-17,23,26,30-32] and a less common, non-obstructive type (Figure 2 HNCM).

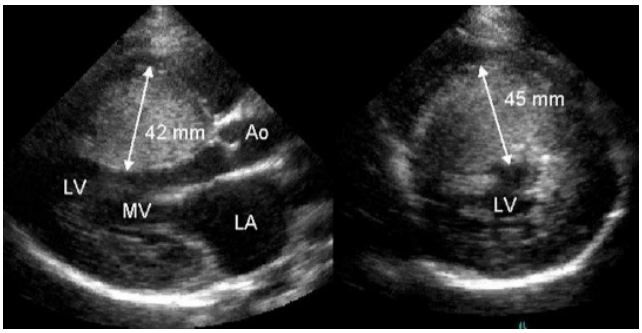

Figure 1: Typical 2D-Echo findings in a HCM-patient with left atrial (LA) dilatation and marked left ventricular (LV) wall thickening particularly involving the interventricular septum.Ao: ascending aorta, MV: mitral valve

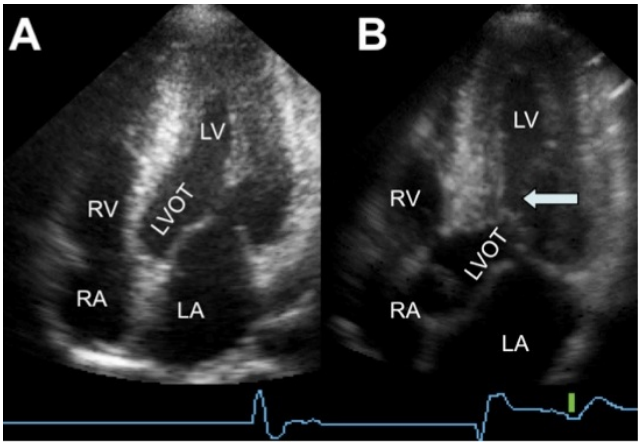

Figure 2: 2D-Echo findings in HNCM (A) with predominant thickening of the apical segments and a wide open, unobstructed outflow tract (LVOT), and in HOCM (B) with a protruding subaortic septum making systolic contact with the mitral valve (SAM-phenomenon, arrow)

Extent and distribution of wall thickening are highly variable; theinterventricular septum is often involved. An American working group [9] suggested that HCM be defined genetically, while the European Working Group on Myocardial and Pericardial Diseases recommended a classification based on morphological and hemodynamic features [10,17]. There is consensus insofar as the hypertrophy process in HCM should be considered as largely genetically determined [63-86]. The inheritance pattern is autosomal dominant with incomplete penetrance. More than 1500 mutations in more than two dozen genes have been identified to date. Beta-myosin heavy chain, cardiac myosin binding protein C, and cardiac troponin T are the most commonly affected proteins, accounting for about 60% to 70% of all cases. About 50% of cases report a familial background of the disease. The mutations described are mostly „single-point missense-mutations“, i.e. a single amino acid is affected. This may result in a truncated or otherwise structurally or functionally alterated

protein. Despite considerable efforts, conclusive genotype-phenotype correlations can still not be made.

Histologically, the prominent findings in HCM are myocardial disarray, hypertrophy, and increased fibrosis [1,86-97]. Cardiomyoctes may be thickened up to 100 µm, and are no longer organized in the regular side-by-side pattern but in whirls and branches. A loss of contractile force may be associated with this cellular disarray, serving as a trigger for the hypertrophy process. Not only the myocardial walls but also the coronary vasulature walls are often thickened which may decrease coronary reserve and lead to myocardial ischemia in the absence of occlusive atherosclerosis [88,95-97]. In addition, interstitial and replacement fibrosis are increased [87,89,92-94], and the mitral valve leaflets often appear enlarged [21,23].

Pathophysiology

Pump function as expressed by left ventricular (LV) ejection fraction (EF) usually remains normal for decades in HCM. However, current parametric imaging techniques usually reveal reduced longitudinal systolic shortening and torsion [98]. In addition, fibrosis and hypertrophy cause reduced distensibility, i.e. diastolic dysfunction early in the clinical course [51,52]. Elevated filling pressures and a reduced stroke volume with stress may thus be present as in other entities characterized as heart failure with preserved ejection fraction"(HfpEF). Left atrial dilatation is thus a typical morphological finding in HCM patients (Figure 1) [57,58]. A late stage of the disease with a dilated left ventricle and reduced ejection fraction may be observed in up to 5% of cases [20,47-49]. Furthermore, fibrosis and disarray are considered as an arrhythmogenic substrate, and myocardial ischemia due to hypertrophy or thickened vessel walls may be a trigger for a wide spectrum of supraventricular and ventricular arrhythmias in HCM patients [50,56-60]. Sudden cardiac death due to ventricular tachyarrhythmias is a feared complication of the disease, and sometimes its first manifestation. Among young (<35 years) athletes dying suddenly, HCM is considered to be responsible in a large percentage of about 30% [8,13,32,41,56,80,99-104]. The dissociation between morphology, functional status, and arrhythmogenic risk is a major problem of HCM management. Sudden cardiac death, often occuring during or after strenuous exercise, is more common in younger and previously asymptomatic patients. Stroke and heart failure related death seems to prevail in elderly cohorts.

Depending on the distribution of hypertrophy within the left ventricle, the septal curvature, the configuration of the mitral valve, and left ventricular loading conditions, a dynamic obstruction with an intracavity systolic pressure gradient (Figure 2 and Figure 3) may result [2,3,7,30-32]. In these cases a "high-pressure" compartment (- in the own series of nearly 1700 patients: up to 400 mm Hg) is separated from a "low-pressure" compartment within the left ventricle. Typically this obstruction is located between the subaortic septum and parts of the mitral valve ("SAM"-phenomenon), and is associated with mitral regurgitation. In a minority of cases it may be located in the midcavity region, or in the apex. Figure 2 shows typical echocardiographic examples of non-obstructive and obstructive HCM, Figure 3. The typical late-peaking cw-Doppler signal of dynamic outflow obstruction in HOCM. Not surprising, a substantial degree of variability has been described regarding gradient severity, and provocation (by physical exercise, pharmacological or physically induced preload reduction, or post-extrasystolic augmentation) is essential to reliably distinguish between HNCM and HOCM both during echocardiographic and invasive hemodynamic studies. 50% of HOCM patients only exhibit obstruction under provocation. The hemodynamic significance of outflow obstruction seems to depend on the size of the LV compartment that is working against increased afterload (subaortic>midcavity obstruction); apical gradients are considered to be insignificant. Reduction of wall thickening following a "de-obstructing" intervention point to the fact that high intracavitypressures are a stimulus for the hypertrophic process [105-107].

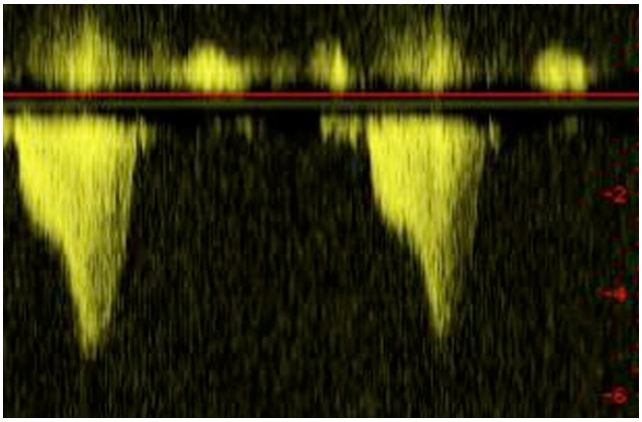

Figure 3: Typical CW-Doppler flow profile of dynamic left ventricular outflow obstruction in HOCM. Note the late-peaking signal indicating to dynamic obstruction involving contracting muscle as opposed to the more symmetrical signal of fixed valvular stenosis. The peak pressure gradient equals 4 x (peak velocity)^2

Signs and symptoms

Typical symptoms in HCM patients are dyspnea, angina, or dizziness on exertion. Palpitations or syncope occurring both with and without exercise are reported by 20-30%. Recurrent syncope and a family history of sudden cardiac death (at <45 years) are considered risk factors for sudden cardiac death [8,13,33]. Overall, a very variable degree of limitation is characteristic. On the other hand, a severe phenotype does not necessarily preclude normal exercise capacity, or even athletic performance.

On auscultation HNCM is usually silent. Occasionally a fourth heart sound can be heard due to increased atrial pressures. In HOCM a systolic murmur can usually be detected due to dynamic obstruction and its associated mitral regurgitation. The Valsalva maneuver or short-acting preload reducers (nitrates) may result in an increase of obstruction and accentuated murmurs, afterload increasement (squatting) diminishes auscultatory findings. Stigmata of systemic diseases occasionally associated with a cardiac phenotype suggesting HCM such as Noonan's syndrome (facial dysmorphia) or Anderson-Fabry disease (typical maculopapular skin lesions) should actively be searched for [112].

ECG

In the majority of HCM patients the ECG shows a left ventricular hypertrophy pattern, about 25% have left anterior hemiblock or a left bundle branch block. The configuration of hypervoltage and giant negative T waves is typical for HNCM, especially the apical variant,

while pseudo-infarct Q waves are often found in HOCM. Peripheral low voltage is suspicious for a storage disease like cardiac amyloidosis, and should trigger considerations about performing a myocardial biopsy [8,13]. A normal ECG does not necessary exclude the presence of HCM but suggests a mild and prognostically benign manifestation of the disease [60,102]. On the other hand, ECG changes may be visible years before the complete morphological phenotype develops.

Imaging studies including echocardiography

The diagnosis of HCM can usually be made by non-invasive imaging techniques (echocardiography, cardiac magnetic resonance imaging, multislice computed tomography: [105,106]; often a multi-modal approach is useful (Figure 4). Highly variable hypertrophy patterns can be seen, ranging from isolated thickening of individual myocardial segments that exceed the normal LV wall thickness of<12 mm by millimeters, up to diffuse and massive hypertrophy of >50 mm. A wall thickness of >30 mm has to be actively looked for since this is considered a risk factor for sudden cardiac death [8,13,20,24,28]. The right ventricle is rarely involved but should not be forgotten [14]. Particular attention should be paid to presence and magnitude of left ventricular outflow obstruction and mitral valve SAM (Figure 3, Figure 4, Figure 5 and Figure 6). Obstruction can be reliably quantified by Doppler assessment of increased systolic outflow velocities (Figure 3 and Figure 5a and 5b). Provocation is mandatory and can be induced pharmacologically, by the Valsalva maneuver, or with ergometric exercise. Postextrasystolic potentiation (Brockenbrough sign, Figure 5aand 5b) is also typical. Consensus documents [8,13] recommend dynamic stress ergometry which may also provide additional prognostic information [31,32]. An increase in afterload or negative inotropic drugs reduces the gradient. Enlargement of the left atrium, reduction of the rapid LV filling phase, and a reduced early mitral annulus velocity on tissue Doppler imaging all indicate to diastolic LV dysfunction. Despite the usually normal or even hyperactive EF, parametric imaging often reveals impaired longitudinal systolic LV performance. Maximal wall thickness and left ventricular muscle mass can also be determined using cardiac MRI and cardiac CT. Myocardial scar tissue can be detected using delayed-enhancement cardiac MRI with Gadolinium contrast (Figure 7). Recent studies indicate to a relationship between the extent of fibrosis, the risk of ventricular arrhythmias, and overall prognosis [48].

Exercise tests and rhythm diagnostics

Objective capacity should be determined using spiroergometry because estimation of symptoms by the patient is often misleading due to adaptation. A preserved exercise capacity was found to be associated with a rather favorableprognosis [32]. Furthermore, exercise testing provides information about blood pressure response to exercise (risk stratification) [8,13]. 48-hour ambulatory Holter ECG recording is needed to detect non-sustained ventricular tachycardia, also essential for risk stratification. The routine use of electrophysiological studies is not recommended [10]. Invasive EPS may be considered in selected patients with documented monomorphic, sustained (>30 s) ventricular tachycardia to identify and treat an abatable arrhythmia substrate [114].

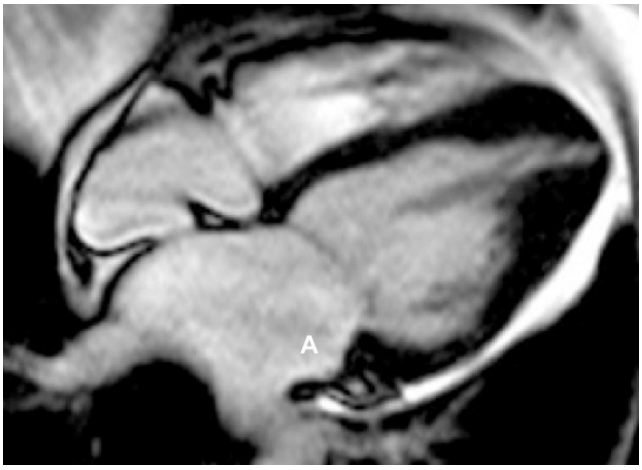

Figure 4: Four-chamber MRI image at end-diastole in a patient who was found to have normal wall thickness on routine 2D echo. Cardiac MRI, however, demonstrated LV wall thickening exclusively in the apical region of the left ventricle, usually less accessible by echocardiography.

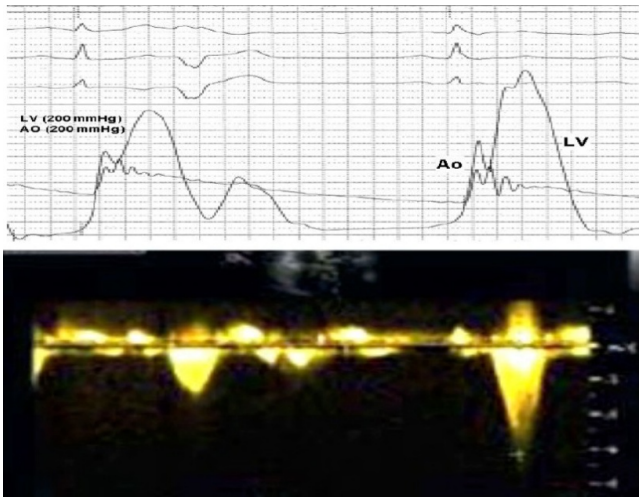

Figure 5: Simultaneous pressure tracing from the LV and the aorta demonstrating the Brocken brough sign. (Abbreviations: LV: Left ventricle; Ao: Aorta).The corresponding Doppler profiles are shown in 5 b. The gradient increases from 40 to 140 mm Hg

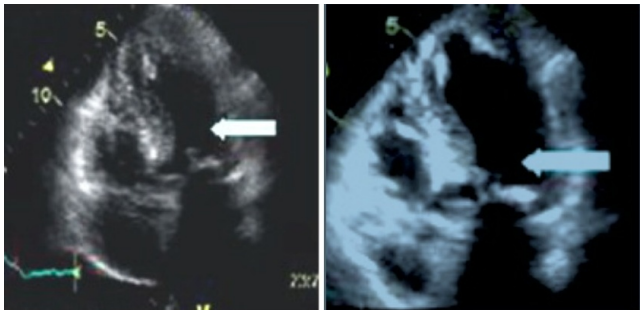

Figure 6: Two different stages of SAM in a HOCM patient: mild (6 a) SAM, leaving the outflow tract open and severe (6 b) with complete septal apposition, producing a high pressure gradient

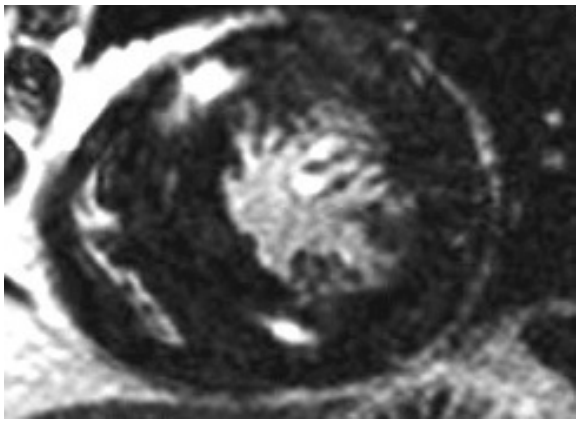

Figure 7: Cardiac MRI short axis view with two bright areas of Gadolonium late enhancement near the left-right ventricular junction

Invasive studies

Cardiac catheterization is performed to exclude or verify coexistent obstructive coronary artery disease, to assess the vascular supply to the septum prior to a planned septal ablation intervention, and to verify myocardial bridging which is controversially discussed as prognostically relevant [8,13,113]. Myocardial biopsies are needed to exclude or verify a storage disease, specifically cardiac amyloidosis. Diastolic LV performance and the outflow gradients can also be assessed invasively; if performed, a provocative maneuver (Valsalva, post-extrasystolic potentiation Figure 5a) with respect to gradient measurement should be included. Invasive electrophysiological studies may be carried out for specific questions like concomitant Wolff-Parkinson-White syndrome (see also: rhythm diagnostics).

Therapeutic options for patients with HCM

General measures

In the absence of large randomized trials, therapeutic recommendations for HCM are mostly based on observational studies or case series. The essentials of the recommendations developed in 2003 by an international expert committee, updated in 2011, are still valid [8,13]. Whether or not obstruction or symptoms are present, HCM patients should not engage in competitive sports [114]. A limitation with respect to moderate physical activities in asymptomatic patients, however, does not seem to be justified. Outflow obstruction may exacerbate with alcohol intake [115], and includes an increased risk for infective endocarditis [116,117]. HCM patients in atrial fibrillation are especially prone to thromboembolic stroke, oral anticoagulation is mandatory in these cases [8,13,58-60]. Avoidance of volume depletion is recommended in order to maintain LV end-diastolic volume and to minimize LVOT obstruction in HOCM.

Risk stratification

All HCM patients should be risk-stratified since the implantation of an ICD reliably reduces arrhythmogenic cardiac events [8,13,33,127-133]. The cardiac mortality rate in unselected patients is reported to be 1% per year; in the age group >60 years, the risk of arrhythmogenic death seems to be specificly low. On the other hand, high-risk subsets carry a 4-5%/year risk of potentially malignant arrhythmias. A survived cardiac arrest or the documentation of a sustained ventricular tachycardia, i.e. secondary prophylaxis of malignant arrhythmogenic events, isa clear indication for an ICD [8,13]. Risk stratification for primary prophylaxis of sudden arrhythmogenic death is more challenging. Five major risk factors have been identified to date, each with a relatively low positive predictive value. Combining them their significance considerably increases [8,13,33]. These risk markers are:

A positive family history of premature sudden cardiac death (SCD, <45 years of age)

A documented non-sustained ventricular tachycardia (NSVT) on 48-hour Holter monitoring

Recurrent unexplained syncope at rest or during exercise

An extreme left ventricular hypertrophy with wall thicknesses >30 mm

An abnormal blood pressure response during exercise, defined as an increase in systolic pressure of <20 mm Hg from baseline value or a pressure drop of >20 mm Hg after an initial increase.

Additional risk factors that are controversially discussed and/or have been studied in smaller patient cohorts are:

Presence of an apical aneurysm

Atrial fibrillation or atrial flutter,

Marked LA dilatation,

A high LVOT gradient,

Evidence of myocardial ischemia,

Early manifestation of HCM and

Myocardial bridging of the LAD

In addition, recent studies consider marked fibrosis as detected by Gadollinium-enhanced cardiac MRI to be associated with an increased risk (90, 108), with respect to both arrhythmic events and to heart failure-related problems. Patients without any of the listed risk markers seem to have a good prognosis. A continuous risk calculation has been recently published by the respective ESC working group (10). Probably the strongest single risk factor is the positive family history of

SCD. An individualized decision must be made for patients with only one of the other first-degree risk marker. Second-degree risk factors may provide additional support.

Medical therapy: HNCM

Medical therapy in HNCM may be considered as HFpEF treatment [8,13,134-136]. In order to optimize filling time, heart rate should be controlled using beta blockers or verapamil-type calcium antagonists. Diuretics and ACE inhibitors/AT receptor antagonists may be used for signs of congestion or concomitant hypertension. Occasionally, an outflow tract obstruction may be produced in initially nonobstructive patients by vigorous afterload reduction, thus we recommend echo Doppler monitoring of the initial phase of therapy. Animal experiments and a recently published study in human HNCM suggest inhibition or even reversal of fibrosis with AT receptor antagonist treatment [137]. Atrial fibrillation with loss of active ventricular filling in HNCM is often associated with a considerable drop in exercise tolerance and an increased risk of embolic events. Anticoagulants should be promptly administered, and Amiodarone can prevent recurrence of atrial fibrillation. Ablation therapy of atrial fibrillation is an additional option; however outcomes are less favorable as compared to patients without structural heart disease [184]. End-stage disease should be treated as severe heart failure of other etiologies, including modern assist device strategies and heart transplantation.

Medical therapy: HOCM

Medical therapy with negative inotropic drugs (beta blockers, calcium antagonists of the verapamil type, disopyramide) is the first line of treatment in order to reduce the outflow gradient and symptoms in HOCM patients [8,13,134-136]. Additional anti-fibrillatory effects may be present for beta blockers, while verapamil is supposed to have a positive effect on diastolic LV function. Beta blocker dosage for symptom control should be up titrated to a resting heart rate 50–60 beats/min. Since about 5-10% of pts. Have a paradoxical response to verapamil; the initiation of verapamil treatment therefore should be monitored closely by echo-Doppler. Overall, the effect of drug treatment often vanishes over the years. Drugs that lead to a marked pre- or afterload reduction, or those with positive inotropic effects are contraindicated in HOCM since they may produce drastic exacerbation of obstruction and hemodynamic collapse. Disopyramide, formerly used for treatment of atrial and ventricular arrhythmias, has strong negative inotropic properties mediated by modulation of sodium-calcium exchange. This action, combined with a vasoconstrictor effect, reduces LVOT obstruction. In central Europe, Disopyramide is no longer available.

Surgical therapy for HOCM

Surgical myotomy/myectomy, developed in the late 50ies and 60ies, traditionally has been the treatment of choice for patients with drug-refractory symptoms and significant (>50 mm Hg) outflow tract obstruction [138-152]. The procedure primarily aims at the substrate of obstruction by removing a part of the protruding septal myocardium (Figure 8), leaves a left bundle branch block on surface ECG in about 50 % of the patients treated, and usually a clearly visible septal trough on imaging studies (Figure 9). If necessary, valvular correction/replacement or coronary bypass grafting can be combined with the reduction of septal myocardium. Success rates of >90% have been reported together with postoperative cardiovascular mortality rates that finally were reduced to <1-2% in experienced centers; the rate of pacemaker dependency is about 5%. A prognostic influence is suspected from long-term observations of post-myectomy patients; however, a randomized study against medical treatment does not exist [153]. It hast to be kept in mind that surgical results obtained at high-volume centers may not be generally replicated. A postoperativecardiac postoperative mortality rate of 5.9%, substantial influenced by concomitant patient morbidity, was recently reported from US registry data [155]. Furthermore, since septal myectomy does not remove the possibility of sudden arrhythmogenic death, SCD risk factor assessment is recommended postoperatively, with ICD placement when indicated.

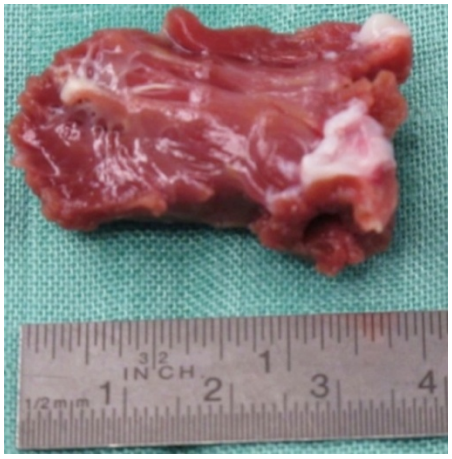

Figure 8: Septal myocardium removed during a myectomy procedure

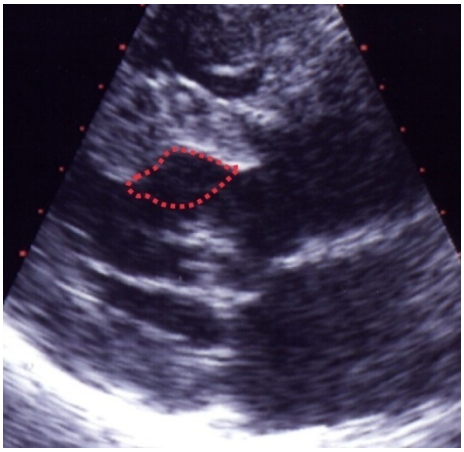

Figure 9: Echocardiographic visualization of the septal trough produced by a myectomy procedure

AV sequential stimulation for HOCM

Dual-chamber pacemaker implantation was introduced as a less invasive alternative to myectomy in the early 90ies. Pacing from the RV apex may be understood as a combination of a global negative inotropic effect and some outflow tract opening due to delayed activation of the basal septum. It also induces a left bundle branch block pattern; a gradient reduction of 50-90% has been reported [154].

Enthusiasm for this approach, however, was soon tempered since a considerable placebo effect became obvious in several randomized trials. At present, we consider AV sequential pacing a "niche indication" for

Patients with left bundle branch block (- and thus a very high risk for complete AV block during septal ablation),

Patients who need an ICD for risk reduction anyway, and

Selected patients with isolated midcavity obstruction

Septal ablation for HOCM

Since the introduction of percutaneous septal ablation therapeutic options for HOCM have substantially changed [155-201]. This procedure produces a circumscript septal infarction by injection of a toxic agent like 96% ethanol into a septal perforator artery supplying the septal bulge. Several acronyms are in use (in alphabetical order, probably not complete: alcohol / ethanol septal ablation (ASA / ESA), non-surgical myocardial reduction (NSMR), percutaneous transluminal septal myocardial ablation (PTSMA), or transcoronary ablation of septal hypertrophy (TASH), reflecting slightly different procedural strategies with or without intra-procedural echocardiography. During the past two decades septal ablation has gained wide acceptance as the non-surgical alternative of choice for patients with hypertrophic cardiomyopathy. The septal lesion produced by the procedure is often undistinguishable from a myectomy trough (Figure10), and it also reproduces the hemodynamic effect of a surgical myectomy. About 60% of the patients treated show a right bundle branch block on surface ECG, and have transient complete heart block during the procedure. Across all reported series including the learning curve of the individual investigator groups, peri-procedural mortality of septal ablation was 1-4%, at present 1-2% [175,178,186,187]. This holds true both for several single-center series and for multicentre registries. The injected ethanol doses gradually decreased over the years (from >5 to 1-3 ml), leading to smaller infarctions and less AV conduction problems. However, the rate of pacemaker implantation still varies considerably (between <5 up to 20%, in patients with pre-existing left bundle branch block: >60%, see above. Following a local remodeling process, the morphologic and hemodynamic treatment result should be judged no earlier than after 3-6 months. At that time point, gradients usually are reduced by 80-90%, associated with an increase in exercise capacity by 20%, reduction of exercise-induced symptoms like dizziness and syncope, and an improvement of diastolic LV function markers.

The available publications on long-term effects of septal ablation also show results comparable to myectomy. Progressive LV dilatation was not observed, thus the remodeling process seems to remain limited to the target region. Not only septal hypertrophy decreased as a consequence of the therapeutic infarction, but also left ventricular free wall thickness due to relief of the pressure overload, which in turn indicates that the hypertrophic process in HOCM may not be completely independent of LV afterload. The incidence of arrhythmic death was particularly low [187,190]. Two meta-analyses compiled non-randomized data comparing clinical outcomes after septal ablation and septal myectomy. Each of these suggests comparable unadjusted mortality rates with the two techniques

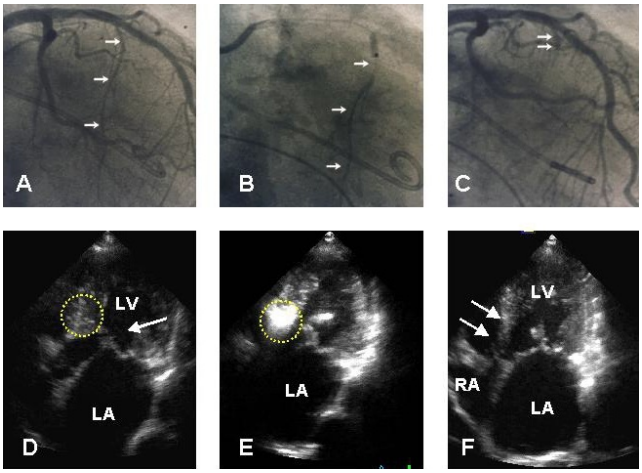

Figure 10: Angiographic (A-C) and echocardiographic (D-F) aspect of an echo-targeted septal ablation procedure (PTSMA) The target vessel (arrows in A) is wired and blocked with an oer-the-wire balloon, verified by contrast injection (arrows in B). The final vessel stump is shown in C (arrows) In D, the dotted circle marks the septal target area including the SAM-septal contact zone. Contrast injection into the target vessel (E) precisely highlights this area. After 3-6 months, akinesia and thinning of the subaortic septumis clearly visible, comparable to a myectomy trough

Septal ablation procedure

A detailed description of the technique has been repeatedly published by our and other groups, differing in several technical aspects. There is consensus that a temporary pacemaker lead is to be inserted in all patients. The LVOT gradient can be constantly monitored by simultaneous pressure recordings from the left ventricular apex and the ascending aorta. An over-the-wire balloon catheter is introduced into the target septal branch presumed to be responsible for the blood supply to the septal area involved in obstruction. The balloon is inflated, and the effect on obstruction measured. In our practice the correct vessel selection is assured by way of injecting 1–2 ml of a non-toxic echocardiographic contrast agent through the central lumen of the balloon catheter under simultaneous transthoracic echocardiographic monitoring. This exactly shows the septal area that will be attacked, i.e. the future area of necrosis (Figure 10). Opacification of any other cardiac structure has to be securely excluded. Currently, in about 5-10% the procedure has to be stopped based on echocardiographic findings (- usually contrast in areas distant from the septal target region), and a target vessel change is necessary for the same reason in 10-15 % [157,158]. Only if the target region is correctly marked by the echo contrast agent, 1-3 ml of 96% alcohol (i.e. 1 ml per 1 cm of septal thickness) are slowly injected through the central lumen of the balloon catheter under analgesic medication. Ten minutes after the last alcohol injection the balloon is deflated and removed, ensuring that no alcohol backwash occurs into the left anterior descending artery. A final angiogram excludes LAD damage and verifies septal branch occlusion, and a final hemodynamic measurement is performed. Glue septal ablation using cyanoacrylate has been suggested to be a safe and effective approach to reduce septal thickness in patients with septal collateral vessels to the right coronary

artery. The authors suggest that immediate glue polymerization prevents its transit through collateral vessels. Significant reductions in LVOT obstruction were observed, but long-term durability of this technique has not yet been demonstrated. Other cytotoxic agents that may be used are microcoils or contour emboli, and small series with less favorableresults reported on the use of radiofrequency energy [196,197].

Patient selection for septal ablation

Criteria for patient selection follow largely those established for septal myectomy. Septal ablation may be considered as an alternative to septal myectomy in:

Patients with symptoms limiting daily activities (Functional class >II, exercise-induced syncope) despite adequate medical treatment, or if medical treatment is not tolerated

Patients with a substantial degree of outflow obstruction (>30 mm Hg at rest or >60-80 mm Hg with provocation by a Valsalva maneuver, bicycle stress in selected cases, or post-extrasystolic augmentation)

Patients with a suitable left ventricular and coronary morphology, i.e. those with a "classical", subaortic obstruction produced by the protruding septum and the "SAM" of the mitral valve, and one or more septal perforator arteries that go to this septal area.

Patients with co-existing, significant coronary artery disease in one vessel only may be treated percutaneously first; ablation should be delayed until documentation of a good long-term result of PCI. In cases with multiple (>1) vessel disease, we prefer a surgical approach. In atypical or midcavity obstruction the decision must be individualized; results are less favorable than in sub aortic obstruction.

Conclusion

Patients with HCM with their different phenotypic presentation need a highly individualized approach both with respect to prognostic and symptomatic aspects, with a near-normal life expectancy and a reasonable quality of life as important aims. Given the relative rarity of either the disease and evidence-based suggestions concerning its management we suggest supervision of the key decisions like risk stratification for ICD implantation, or differential approach to outflow obstruction in experienced institutions. About 90% of the patients with severely symptomatic HOCM of the subaortic type can be treated effectively with septal ablation, making this procedure an attractive alternative to the „gold standard"of surgical myectomy. The procedure requires a careful patient selection, should be part of a comprehensive program for HCM patients who offer all other options (medical treatment, myectomy, and pacemaker- and ICD implantation), results in a significant and long-standing clinical and hemodynamic benefit, and appears to have an acceptable safety profile.

References

1. TEARE D (1958) Asymmetrical hypertrophy of the heart in young adults. Br Heart J 20: 1-8.
2. Braunwald E, Lambrew Ct, Rockoff Sd, Ross J Jr, Morrow Ag (1964) Idiopathic Hypertrophic Subaortic Stenosis. I. A Description Of The Disease Based Upon An Analysis Of 64 Patients. Circulation 30: Suppl 4:3-119.
3. Frank S, Braunwald E (1968) Idiopathic hypertrophic subaortic stenosis. Clinical analysis of 126 patients with emphasis on the natural history. Circulation 37: 759-788.
4. Maron BJ (2004) Hypertrophic cardiomyopathy: an important global disease. Am J Med 116: 63-65.
5. Maron BJ (2002) Hypertrophic cardiomyopathy: a systematic review. JAMA 287: 1308-1320.
6. Spirito P, Seidman CE, McKenna WJ, Maron BJ (1997) The management of hypertrophic cardiomyopathy. N Engl J Med 336: 775-785.
7. Wigle ED, Rakowski H, Kimball BP, Williams WG (1995) Hypertrophic cardiomyopathy. Clinical spectrum and treatment. Circulation 92: 1680-1692.
8. Maron BJ, McKenna WJ, Danielson GK, Kappenberger LJ, Kuhn HJ, et al. (2003) American College of Cardiology/European Society of Cardiology clinical expert consensus document on hypertrophic cardiomyopathy. A report of the American College of Cardiology Foundation Task Force on Clinical Expert Consensus Documents and the European Society of Cardiology Committee for Practice Guidelines. J Am Coll Cardiol 42: 1687-1713.
9. Maron BJ, Seidman CE, Ackerman MJ, et al. (2009) How should hypertrophic cardiomyopathy be classified? What's in a name? Dilemmas in nomenclature characterizing hypertrophic cardiomyopathy and left ventricular hypertrophy. Circ Cardiovasc Genet 2: 81–85.
10. Authors/Task Force members, Elliott PM, Anastasakis A, Borger MA, Borggrefe M, et al. (2014) 2014 ESC Guidelines on diagnosis and management of hypertrophic cardiomyopathy: the Task Force for the Diagnosis and Management of Hypertrophic Cardiomyopathy of the European Society of Cardiology (ESC). Eur Heart J 35: 2733-2779.
11. Maron BJ, Gardin JM, Flack JM, Gidding SS, Kurosaki TT, et al. (1995) Prevalence of hypertrophic cardiomyopathy in a general population of young adults: echocardiographic analysis of 4111 subjects in the CARDIA Study. Circulation 92: 785–789.
12. Kitaoka H, Doi Y, Casey SA, Hitomi N, Furuno T, et al. (2003) Comparison of prevalence of apical hypertrophic cardiomyopathy in Japan and the United States. Am J Cardiol 92: 1183-1186.
13. Maron BJ, Olivotto I, Spirito P, Casey SA, Bellone P, et al. (2000) Epidemiology of hypertrophic cardiomyopathy-related death: revisited in a large non-referral-based patient population. Circulation 102: 858-864.
14. Gersh BJ, Maron BJ, Bonow RO, et al. (2011) ACCF/AHA guidelines for the diagnosis and treatment of hypertrophic cardiomyopathy: a report of the American College of Cardiology Foundation/ American Heart Association Task Force on practice guidelines. J Am Coll Cardiol 58: 212–260.
15. Maron MS, Hauser TH, Dubrow E, Horst TA, Kissinger KV, et al. (2007) Right ventricular involvement in hypertrophic cardiomyopathy. Am J Cardiol 100: 1293-1298.
16. Prinz C, Farr M, Hering D, Horstkotte D, Faber L (2011) The diagnosis and treatment of hypertrophic cardiomyopathy. Dtsch Arztebl Int 108: 209-215.
17. Maron BJ, Maron MS (2013) Hypertrophic cardiomyopathy. Lancet 381: 242-255.
18. Rapezzi C, Arbustini E, Caforio AL, Charron P, Gimeno-Blanes J, et al. (2013) Diagnostic work-up in cardiomyopathies: bridging

the gap between clinical phenotypes and final diagnosis: A position statement from the ESC Working Group on myocardial and Pericardial Diseases: Eur Heart J 34: 1448-1458.

19. Klues HG, Schiff ers A, Maron BJ (1995) Phenotypic spectrum and patterns of left ventricular hypertrophy in hypertrophic cardiomyopathy: morphologic observations and significance as assessed by two-dimensional echocardiography in 600 patients. J Am Coll Cardiol 26: 1699–1708.
20. Maron BJ, Spirito P, Wesley Y, Arce J (1986) Development and progression of left ventricular hypertrophy in children with hypertrophic cardiomyopathy. N Engl J Med 315: 610-614.
21. Harris KM, Spirito P, Maron MS, Zenovich AG, Formisano F, et al. (2006) Prevalence, clinical profile, and significance of left ventricular remodeling in the end-stage phase of hypertrophic cardiomyopathy. Circulation 114: 216-225.
22. Klues HG, Maron BJ, Dollar AL, Roberts WC (1992) Diversity of structural mitral valve alterations in hypertrophic cardiomyopathy. Circulation 85: 1651-1660.
23. Maron MS, Olivotto I, Harrigan C, et al. (2011) Mitral valve abnormalities identified by cardiovascular magnetic resonance represent a primary phenotypic expression of hypertrophic cardiomyopathy. Circulation 124: 40–47.
24. Schwammenthal E, Nakatani S, He S, Hopmeyer J, Sagie A, (1998) Mechanism of mitral regurgitation in hypertrophic cardiomyopathy: mismatch of posterior to anterior leaflet length and mobility. Circulation 98: 856-865.
25. Maron MS, Zenovich AG, Casey SA, Link MS, Udelson JE, et al. (2005) Significance and relation between magnitude of left ventricular hypertrophy and heart failure symptoms in hypertrophic cardiomyopathy. Am J Cardiol 95: 1329-1333.
26. Shah PM, Taylor RD, Wong M (1981) Abnormal mitral valve coaptation in hypertrophic obstructive cardiomyopathy: proposed role in systolic anterior motion of mitral valve. Am J Cardiol 48: 258-262.
27. Maron BJ, Harding AM, Spirito P, Roberts WC, Waller BF (1983) Systolic anterior motion of the posterior mitral leaflet: a previously unrecognized cause of dynamic subaortic obstruction in patients with hypertrophic cardiomyopathy. Circulation 168: 282–293.
28. Klues HG, Roberts WC, Maron BJ (1991) Anomalous insertion of papillary muscle directly into anterior mitral leafl et in hypertrophic cardiomyopathy: significance in producing left ventricular outflow obstruction. Circulation 1991; 84: 1188–97.
29. Spirito P, Bellone P, Harris KM, Bernabo P, Bruzzi P, et al. (2000) Magnitude of left ventricular hypertrophy and risk of sudden death in hypertrophic cardiomyopathy. N Engl J Med 342: 1778-1785.
30. Olivotto I, Maron MS, Autore C, Lesser JR, Rega L, et al. (2008) Assessment and significance of left ventricular mass by cardiovascular magnetic resonance in hypertrophic cardiomyopathy. J Am Coll Cardiol 52: 559-566.
31. Maron MS, Olivotto I, Zenovich AG, Link MS, Pandian NG, et al. (2006) Hypertrophic cardiomyopathy is predominantly a disease of left ventricular outflow tract obstruction. Circulation 114: 2232-2239.
32. Peteiro J, Bouzas-Mosquera A, Fernandez X, Monserrat L, Pazos P, et al. (2012) Prognostic value of exercise echocardiography in patients with hypertrophic cardiomyopathy. J Am Soc Echocardiogr 25: 182-189.
33. Desai MY, Bhonsale A2, Patel P2, Naji P2, Smedira NG2, et al. (2014) Exercise echocardiography in asymptomatic HCM: exercise capacity, and not LV outflow tract gradient predicts long-term outcomes. JACC Cardiovasc Imaging 7: 26-36.
34. Elliott PM, Poloniecki J, Dickie S, Sharma S, Monserrat L, et al. (2000) Sudden death in hypertrophic cardiomyopathy: identification of high risk patients. J Am Coll Cardiol 36: 2212-2218.
35. Maron BJ (2010) Contemporary insights and strategies for risk stratification and prevention of sudden death in hypertrophic cardiomyopathy. Circulation 121: 445-456.
36. Maron MS, Maron BJ, Harrigan C, Buros J, Gibson CM, et al. (2009) Hypertrophic cardiomyopathy phenotype revisited after 50 years with cardiovascular magnetic resonance. J Am Coll Cardiol 54: 220-228.
37. Rickers C, Wilke NM, Jerosch-Herold M, Casey SA, Panse P, et al. (2005) Utility of cardiac magnetic resonance imaging in the diagnosis of hypertrophic cardiomyopathy. Circulation 112: 855-861.
38. Moon JC, Fisher NG, McKenna WJ, Pennell DJ (2004) Detection of apical hypertrophic cardiomyopathy by cardiovascular magnetic resonance in patients with non-diagnostic echocardiography. Heart 90: 645-649.
39. Elliott PM, Gimeno Blanes JR, Mahon NG, Poloniecki JD, McKenna WJ (2001) Relation between severity of left-ventricular hypertrophy and prognosis in patients with hypertrophic cardiomyopathy. Lancet 357: 420-424.
40. Maron BJ, Casey SA, Poliac LC, Gohman TE, Almquist AK, et al. (1999) Clinical course of hypertrophic cardiomyopathy in a regional United States cohort. JAMA 281: 650-655.
41. Olivotto I, Maron MS, Adabag AS, Casey SA, Vargiu D, et al. (2005) Gender-related differences in the clinical presentation and outcome of hypertrophic cardiomyopathy. J Am Coll Cardiol 46: 480-487.
42. Maron BJ, Carney KP, Lever HM, Lewis JF, Barac I, et al. (2003) Relationship of race to sudden cardiac death in competitive athletes with hypertrophic cardiomyopathy. J Am Coll Cardiol 41: 974-980.
43. Adabag AS, Kuskowski MA, Maron BJ (2006) Determinants for clinical diagnosis of hypertrophic cardiomyopathy. Am J Cardiol 98: 1507-1511.
44. Corrado D, Basso C, Schiavon M, Thiene G (1998) Screening for hypertrophic cardiomyopathy in young athletes. N Engl J Med 339: 364-369.
45. Maron MS, Finley JJ, Bos JM, Hauser TH, Manning WJ, et al. (2008) Prevalence, clinical significance, and natural history of left ventricular apical aneurysms in hypertrophic cardiomyopathy. Circulation 118: 1541-1549.
46. Maron MS, Lesser JR, Maron BJ (2010) Management implications of massive left ventricular hypertrophy in hypertrophic cardiomyopathy significantly underestimated by echocardiography but identified by cardiovascular magnetic resonance. Am J Cardiol 105: 1842–1843.
47. Braunwald E (2012) Obstruction in hypertrophic cardiomyopathy: how often does it occur? Should it be treated? If so, how? Circulation 126: 2369-2370.
48. Olivotto I, Maron BJ, Appelbaum E, et al. (2010) Spectrum and clinical significance of systolic function and myocardial fibrosis

assessed by cardiovascular magnetic resonance in hypertrophic cardiomyopathy. Am J Cardiol 106: 261–267.

49. Maron MS, Kalsmith BM, Udelson JE, Li W, DeNofrio D (2010) Survival after cardiac transplantation in patients with hypertrophic cardiomyopathy. Circ Heart Fail 3: 574-579.
50. Topilsky Y, Pereira NL, Shah DK, Boilson B, Schirger JA, et al. (2011) Left ventricular assist device therapy in patients with restrictive and hypertrophic cardiomyopathy. Circ Heart Fail 4: 266-275.
51. Kubo T, Kitaoka H, Okawa M, Hirota T, Hayato K, et al. (2009) Clinical impact of atrial fibrillation in patients with hypertrophic cardiomyopathy. Results from Kochi RYOMA Study. Circ J 73: 1599-1605.
52. Geske JB, Sorajja P, Nishimura RA, Ommen SR (2007) Evaluation of left ventricular filling pressures by Doppler echocardiography in patients with hypertrophic cardiomyopathy: correlation with direct left atrial pressure measurement at cardiac catheterization. Circulation 116: 2702–208.
53. Maron BJ, Spirito P, Green KJ, Wesley YE, Bonow RO, et al. (1987) Noninvasive assessment of left ventricular diastolic function by pulsed Doppler echocardiography in patients with hypertrophic cardiomyopathy. J Am Coll Cardiol 10: 733-742.
54. Autore C, Bernabò P, Barillà CS, Bruzzi P, Spirito P (2005) The prognostic importance of left ventricular outflow obstruction in hypertrophic cardiomyopathy varies in relation to the severity of symptoms. J Am Coll Cardiol 45: 1076-1080.
55. Elliott PM, Gimeno JR, Tomé MT, Shah J, Ward D, et al. (2006) Left ventricular outflow tract obstruction and sudden death risk in patients with hypertrophic cardiomyopathy. Eur Heart J 27: 1933-1941.
56. Maron MS, Olivotto I, Betocchi S, Casey SA, Lesser JR, et al. (2003) Effect of left ventricular outflow tract obstruction on clinical outcome in hypertrophic cardiomyopathy. N Engl J Med 348: 295-303.
57. McKenna WJ, Deanfield JE (1984) Hypertrophic cardiomyopathy: an important cause of sudden death. Arch Dis Child 59: 971-975.
58. Olivotto I, Cecchi F, Casey SA, Dolara A, Traverse JH, et al. (2001) Impact of atrial fibrillation on the clinical course of hypertrophic cardiomyopathy. Circulation 104: 2517-2524.
59. Maron BJ, Olivotto I, Bellone P, Conte MR, Cecchi F, et al. (2002) Clinical profile of stroke in 900 patients with hypertrophic cardiomyopathy. J Am Coll Cardiol 39: 301-307.
60. Maron BJ, Casey SA, Hauser RG, Aeppli DM (2003) Clinical course of hypertrophic cardiomyopathy with survival to advanced age. J Am Coll Cardiol 42: 882-888.
61. Maron BJ, Casey SA, Haas TS, Kitner CL, Garberich RF, et al. (2012) Hypertrophic cardiomyopathy with longevity to 90 years or older. Am J Cardiol 109: 1341-1347.
62. McLeod CJ, Ackerman MJ, Nishimura RA, Tajik AJ, Gersh BJ, et al. (2009) Outcome of patients with hypertrophic cardiomyopathy and a normal electrocardiogram. J Am Coll Cardiol 54: 229-233.
63. Alcalai R, Seidman JG, Seidman CE (2008) Genetic basis of hypertrophic cardiomyopathy: from bench to the clinics. J Cardiovasc Electrophysiol 19: 104-110.
64. Seidman CE, Seidman JG (2011) Identifying sarcomere gene mutations in hypertrophic cardiomyopathy: a personal history. Circ Res 108: 743-750.
65. Ackerman MJ, VanDriest SL, Ommen SR, et al. (2002) Prevalence and age-dependence of malignant mutations in the beta-myosin heavy chain and troponin T genes in hypertrophic cardiomyopathy: a comprehensive outpatient perspective. J Am Coll Cardiol 39: 2042–2048.
66. Niimura H, Bachinski LL, Sangwatanaroj S, Watkins H, Chudley AE, et al. (1998) Mutations in the gene for cardiac myosin-binding protein C and late-onset familial hypertrophic cardiomyopathy. N Engl J Med 338: 1248-1257.
67. Van Driest SL, Ackerman MJ, Ommen SR, et al. (2002) Prevalence and severity of "benign" mutations in the beta-myosin heavy chain, cardiac troponin T, and alpha-tropomyosin genes in hypertrophic cardiomyopathy. Circulation 106: 3085–3090.
68. Landstrom AP, Ackerman MJ (2010) Mutation type is not clinically useful in predicting prognosis in hypertrophic cardiomyopathy. Circulation 122: 2441-2449.
69. Richard P, Charron P, Carrier L, et al. (2003) Hypertrophic cardiomyopathy: distribution of disease genes, spectrum of mutations, and implications for a molecular diagnosis strategy. Circulation 107: 2227–2232.
70. Jiang J, Wakimoto H, Seidman JG, Seidman CE (2013) Allele-specific silencing of mutant Myh6 transcripts in mice suppresses hypertrophic cardiomyopathy. Science 342: 111-114.
71. Seidman JG, Seidman C (2001) The genetic basis for cardiomyopathy: from mutation identification to mechanistic paradigms. Cell 104: 557-567.
72. Maron BJ, Seidman JG, Seidman CE (2004) Proposal for contemporary screening strategies in families with hypertrophic cardiomyopathy. J Am Coll Cardiol 44: 2125-2132.
73. Gruner C, Care M, Siminovitch K, Moravsky G, Wigle ED, et al. (2011) Sarcomere protein gene mutations in patients with apical hypertrophic cardiomyopathy. Circ Cardiovasc Genet 4: 288-295.
74. Christiaans I, Lekanne dit Deprez RH, van Langen IM, Wilde AA (2009) Ventricular fibrillation in MYH7-related hypertrophic cardiomyopathy before onset of ventricular hypertrophy. Heart Rhythm 6: 1366–1369.
75. Arad M, Penas-Lado M, Monserrat L, Maron BJ, Sherrid M, et al. (2005) Gene mutations in apical hypertrophic cardiomyopathy. Circulation 112: 2805-2811.
76. Morita H, Rehm HL, Menesses A, McDonough B, Roberts AE, et al. (2008) Shared genetic causes of cardiac hypertrophy in children and adults. N Engl J Med 358: 1899-1908.
77. Ho CY, Sweitzer NK, McDonough B, et al. (2002) Assessment of diastolic function with Doppler tissue imaging to predict genotype in preclinical hypertrophic cardiomyopathy. Circulation 105: 2992–2997.
78. Maron BJ, Yeates L, Semsarian C (2011) Clinical challenges of genotype positive (+)-phenotype negative (-) family members in hypertrophic cardiomyopathy. Am J Cardiol 107: 604-608.
79. Maron BJ, Niimura H, Casey SA, Soper MK, Wright GB, et al. (2001) Development of left ventricular hypertrophy in adults in hypertrophic cardiomyopathy caused by cardiac myosin-binding protein C gene mutations. J Am Coll Cardiol 38: 315-321.
80. Watkins H, Rosenzweig A, Hwang DS, Levi T, McKenna W, et al. (1992) Characteristics and prognostic implications of myosin missense mutations in familial hypertrophic cardiomyopathy. N Engl J Med 326: 1108-1114.

81. Watkins H (2000) Sudden death in hypertrophic cardiomyopathy. N Engl J Med 342: 422-424.
82. Kelly M, Semsarian C (2009) Multiple mutations in genetic cardiovascular disease: a marker of disease severity? Circ Cardiovasc Genet 2: 182-190.
83. Maron BJ, Maron MS, Semsarian C (2012) Double or compound sarcomere mutations in hypertrophic cardiomyopathy: a potential link to sudden death in the absence of conventional risk factors. Heart Rhythm 9: 57-63.
84. Maron BJ, Roberts WC, Arad M, Haas TS, Spirito P, et al. (2009) Clinical outcome and phenotypic expression in LAMP2 cardiomyopathy. JAMA 301: 1253-1259.
85. Kubo T, Gimeno JR, Bahl A, Steffensen U, Steffensen M, et al. (2007) Prevalence, clinical significance, and genetic basis of hypertrophic cardiomyopathy with restrictive phenotype. J Am Coll Cardiol 49: 2419-2426.
86. Bos JM, Towbin JA, Ackerman MJ (2009) Diagnostic, prognostic, and therapeutic implications of genetic testing for hypertrophic cardiomyopathy. J Am Coll Cardiol 54: 201-211.
87. Maron BJ, Roberts WC (1979) Quantitative analysis of cardiac muscle cell disorganization in the ventricular septum of patients with hypertrophic cardiomyopathy. Circulation 59: 689-706.
88. Ho CY, López B, Coelho-Filho OR, Lakdawala NK, Cirino AL, et al. (2010) Myocardial fibrosis as an early manifestation of hypertrophic cardiomyopathy. N Engl J Med 363: 552-563.
89. Maron BJ, Wolfson JK, Epstein SE, Roberts WC (1986) Intramural ("small vessel") coronary artery disease in hypertrophic cardiomyopathy. J Am Coll Cardiol 8: 545-557.
90. Shirani J, Pick R, Roberts WC, Maron BJ (2000) Morphology and significance of the left ventricular collagen network in young patients with hypertrophic cardiomyopathy and sudden cardiac death. J Am Coll Cardiol 35: 36-44.
91. Prinz C, Schwarz M, Ilic I, Laser KT, Lehmann R, et al. (2013) Myocardial Fibrosis Severity on Cardiac Magnetic Resonance Imaging Predicts Sustained Arrhythmic Events in Hypertrophic Cardiomyopathy. Can J Cardiol 29: 358-363.
92. Prinz C, Van Buuren F, Bogunovic N, Bitter T, Faber L, et al. (2012) In patients with hypertrophic cardiomyopathy myocardial fibrosis is associated with both left ventricular and left atrial dysfunction. Acta Cardiol 67: 187-193.
93. Prinz C, van Buuren F, Faber L, Bitter T, Bogunovic N, et al. (2012) Myocardial fibrosis is associated with biventricular dysfunction in patients with hypertrophic cardiomyopathy. Echocardiography 29: 438-444.
94. Prinz C, Hering D, Bitter T, Horstkotte D, Faber L (2011) Left atrial size and left ventricular hypertrophy correlate with myocardial fibrosis in patients with hypertrophic cardiomyopathy. Acta Cardiol 66: 153-157.
95. Prinz C, Farr M, Laser KT, Esdorn H, Piper C, et al. (2013) Determining the role of fibrosis in hypertrophic cardiomyopathy. Expert Rev Cardiovasc Ther 11: 495-504.
96. Maron MS, Olivotto I, Maron BJ, Prasad SK, Cecchi F, et al. (2009) The case for myocardial ischemia in hypertrophic cardiomyopathy. J Am Coll Cardiol 54: 866-875.
97. Olivotto I, Cecchi F, Gistri R, Lorenzoni R, Chiriatti G, et al. (2006) Relevance of coronary microvascular flow impairment to long-term remodeling and systolic dysfunction in hypertrophic cardiomyopathy. J Am Coll Cardiol 47: 1043-1048.
98. Cecchi F, Olivotto I, Gistri R, Lorenzoni R, Chiriatti G, et al. (2003) Coronary microvascular dysfunction and prognosis in hypertrophic cardiomyopathy. N Engl J Med 349: 1027-1035.
99. Basso C, Thiene G, Corrado D, Buja G, Melacini P, et al. (2000) Hypertrophic cardiomyopathy and sudden death in the young: pathologic evidence of myocardial ischemia. Hum Pathol 31: 988-998.
100. Prinz C, Faber L1, Horstkotte D1, Körperich H2, Moysich A2, et al. (2014) Evaluation of left ventricular torsion in children with hypertrophic cardiomyopathy. Cardiol Young 24: 245-252.
101. Maron BJ, Pelliccia A (2006) The heart of trained athletes: cardiac remodeling and the risks of sports, including sudden death. Circulation 114: 1633-1644.
102. Corrado D, Basso C, Pavei A, Michieli P, Schiavon M, et al. (2006) Trends in sudden cardiovascular death in young competitive athletes after implementation of a preparticipation screening program. JAMA 296: 1593–1601.
103. Maron BJ (2001) The electrocardiogram as a diagnostic tool for hypertrophic cardiomyopathy: revisited. Ann Noninvasive Electrocardiol 6: 277-279.
104. Maron BJ (2001) The electrocardiogram as a diagnostic tool for hypertrophic cardiomyopathy: revisited. Ann Noninvasive Electrocardiol 6: 277-279.
105. Rowin EJ, Maron BJ, Appelbaum E, Link MS, Gibson CM, et al. (2012) Significance of false negative electrocardiograms in preparticipation screening of athletes for hypertrophic cardiomyopathy. Am J Cardiol 110: 1027-1032.
106. Decker JA, Rossano JW, Smith EO, Cannon B, Clunie SK, et al. (2009) Risk factors and mode of death in isolated hypertrophic cardiomyopathy in children. J Am Coll Cardiol 54: 250-254.
107. Rowin EJ, Maron MS, Lesser JR, Maron BJ (2012) CMR with late gadolinium enhancement in genotype positive-phenotype negative hypertrophic cardiomyopathy. JACC Cardiovasc Imaging 5: 119-122.
108. Germans T, Wilde AA, Dijkmans PA, et al. (2006) Structural abnormalities of the inferoseptal left ventricular wall detected by cardiac magnetic resonance imaging in carriers of hypertrophic cardiomyopathy mutations. J Am Coll Cardiol 48: 2518–2523.
109. Butz T, van Buuren F, Mellwig KP, Langer C, Plehn G, et al. (2011) Two-dimensional strain analysis of the global and regional myocardial function for the differentiation of pathologic and physiologic left ventricular hypertrophy: a study in athletes and in patients with hypertrophic cardiomyopathy. Int J Cardiovasc Imaging 27:91-100.
110. Chan R, Maron BJ, Olivotto I, Assienza G, Hong S, et al. (2012) Prognostic utility of contrast-enhanced cardiovascular magnetic resonance in hypertrophic cardiomyopathy: an international multicenter study. J Am Coll Cardiol 59: 1570.
111. Faber L, Prinz C, Hering D, Butz T, Oldenburg O, et al. (2011) Peak systolic longitudinal strain of the lateral left ventricular wall improves after septal ablation for symptomatic hypertrophic obstructive cardiomyopathy: A follow-up study using speckle tracking echocardiography. Int J Cardiovasc Imaging 27: 325-333.
112. Mazur W, Nagueh SF, Lakkis NM, Middleton KJ, Killip D, et al. (2001) Regression of left ventricular hypertrophy after nonsurgical septal reduction therapy for hypertrophic obstructive cardiomyopathy. Circulation 103: 1492-1496.

113. Dimitriadis Z, van Buuren F, Bogunovic N, Horstkotte D, Faber L (2012) Marked Regression of Left Ventricular Hypertrophy after Outflow Desobliteration in HOCM. Case Rep Med 2012: 546942.
114. Dimitriadis Z, van Buuren F, Bogunovic N, Horstkotte D, Faber L (2012) Marked Regression of Left Ventricular Hypertrophy after Outflow Desobliteration in HOCM. Case Rep Med 2012: 546942.
115. Weidemann F, Niemann M, Breunig F, Herrmann S, Beer M, et al. (2009) Long-term effects of enzyme replacement therapy on fabry cardiomyopathy: evidence for a better outcome with early treatment. Circulation 119: 524-529.
116. Lim KK, Maron BJ, Knight BP (2009) Successful catheter ablation of hemodynamically unstable monomorphic ventricular tachycardia in a patient with hypertrophic cardiomyopathy and apical aneurysm. J Cardiovasc Electrophysiol20:445–447.
117. Basso C, Thiene G, Mackey-Bojack S, Frigo AC, Corrado D, et al. (2009) Myocardial bridging, a frequent component of the hypertrophic cardiomyopathy phenotype, lacks systematic association with sudden cardiac death. Eur Heart J 30: 1627–1634.
118. Pelliccia A, Fagard R, Bjornstad HH, et al. (2005) Recommendations for competitive sports participation in athletes with cardiovascular disease: a consensus document from the Study Group of Sports Cardiology of the Working Group of Cardiac Rehabilitation and Exercise Physiology and the Working Group of Myocardial and Pericardial Diseases of the European Society of Cardiology. Eur Heart J 26: 1422–1445.
119. Paz R, Jortner R, Tunick PA, Sclarovsky S, Eilat B, et al. (1996) The effect of the ingestion of ethanol on obstruction of the left ventricular outflow tract in hypertrophic cardiomyopathy. N Engl J Med 335: 938-941.
120. Maron BJ, Lever H (2009) In defense of antimicrobial prophylaxis for prevention of infective endocarditis in patients with hypertrophic cardiomyopathy. J Am Coll Cardiol 54: 2339-2340.
121. Spirito P, Rapezzi C, Bellone P, et al. (1999) Infective endocarditis in hypertrophic cardiomyopathy: prevalence, incidence, and indications for antibiotic prophylaxis. Circulation 99: 2132–2137.
122. Maron BJ, Shen WK, Link MS, Epstein AE, Almquist AK, et al. (2000) Efficacy of implantable cardioverter-defibrillators for the prevention of sudden death in patients with hypertrophic cardiomyopathy. N Engl J Med 342: 365-373.
123. Maron BJ, Spirito P, Shen WK, Haas TS, Formisano F, et al. (2007) Implantable cardioverter-defibrillators and prevention of sudden cardiac death in hypertrophic cardiomyopathy. JAMA 298: 405-412.
124. Maron BJ, Doerer JJ, Haas TS, Tierney DM, Mueller FO (2009) Sudden deaths in young competitive athletes: analysis of 1866 deaths in the United States, 1980-2006. Circulation 119: 1085-1092.
125. Maron BJ, Maron MS, Lesser JR, Hauser RG, Haas TS, et al. (2008) Sudden cardiac arrest in hypertrophic cardiomyopathy in the absence of conventional criteria for high risk status. Am J Cardiol 101: 544-547.
126. Maron BJ, Semsarian C, Shen WK, et al. (2009) Circadian patterns in the occurrence of malignant ventricular tachyarrhythmias triggering defibrillator interventions in patients with hypertrophic cardiomyopathy. Heart Rhythm 6: 599–602.
127. Spirito P, Autore C, Rapezzi C, Bernabò P, Badagliacca R, et al. (2009) Syncope and risk of sudden death in hypertrophic cardiomyopathy. Circulation 119: 1703-1710.
128. Maron BJ, Haas TS, Shannon KM, Almquist AK, Hodges JS (2009) Long-term survival after cardiac arrest in hypertrophic cardiomyopathy. Heart Rhythm 6: 993-997.
129. Maron BJ, Spirito P (2008) Implantable defibrillators and prevention of sudden death in hypertrophic cardiomyopathy. J Cardiovasc Electrophysiol 19: 1118-1126.
130. Monserrat L, Elliott PM, Gimeno JR, Sharma S, Penas-Lado M, et al. (2003) Non-sustained ventricular tachycardia in hypertrophic cardiomyopathy: an independent marker of sudden death risk in young patients. J Am Coll Cardiol 42: 873-879.
131. Epstein AE, DiMarco JP, Ellenbogen KA, et al. (2008) ACC/AHA/HRS 2008 guidelines for device-based therapy of cardiac rhythm abnormalities: executive summary—a report of the American College of Cardiology/American Heart Association Task Force on practice guidelines (writing committee to revise the ACC/AHA/ NASPE 2002 guideline update for implantation of cardiac pacemakers and antiarrhythmia devices) developed in collaboration with the American Association for Thoracic Surgery and Society of Thoracic Surgeons. J Am Coll Cardiol 51: 2085–2105.
132. Adabag AS, Maron BJ, Appelbaum E, Harrigan CJ, Buros JL, et al. (2008) Occurrence and frequency of arrhythmias in hypertrophic cardiomyopathy in relation to delayed enhancement on cardiovascular magnetic resonance. J Am Coll Cardiol 51: 1369-1374.
133. Melacini P, Maron BJ, Bobbo F, Basso C, Tokajuk B, et al. (2007) Evidence that pharmacological strategies lack efficacy for the prevention of sudden death in hypertrophic cardiomyopathy. Heart 93: 708-710.
134. Berul CI, Van Hare GF, Kertesz NJ, et al. (2008) Results of a multicenter retrospective implantable cardioverter-defibrillator registry of pediatric and congenital heart disease patients. J Am Coll Cardiol 51: 1685–1691.
135. Dukkipati SR, d'Avila A, Soejima K, et al. (2011) Long-term outcomes of combined epicardial and endocardial ablation of monomorphic ventricular tachycardia related to hypertrophic cardiomyopathy. Circ Arrhythm Electrophysiol 4: 185–194.
136. Hauser RG, Maron BJ (2005) Lessons from the failure and recall of an implantable cardioverter-defibrillator. Circulation 112: 2040-2042.
137. Melacini P, Basso C, Angelini A, Calore C, Bobbo F, et al. (2010) Clinicopathological profiles of progressive heart failure in hypertrophic cardiomyopathy. Eur Heart J 31: 2111-2123.
138. Maron BJ, Tholakanahalli VN, Zenovich AG, Casey SA, Duprez D, et al. (2004) Usefulness of B-type natriuretic peptide assay in the assessment of symptomatic state in hypertrophic cardiomyopathy. Circulation 109: 984-989.
139. Sherrid MV, Barac I, McKenna WJ, Elliott PM, Dickie S, et al. (2005) Multicenter study of the efficacy and safety of disopyramide in obstructive hypertrophic cardiomyopathy. J Am Coll Cardiol 45: 1251-1258.
140. Nistri S, Olivotto I, Maron MS, Ferrantini C, Coppini R, et al. (2012) Î² Blockers for prevention of exercise-induced left

ventricular outflow tract obstruction in patients with hypertrophic cardiomyopathy. Am J Cardiol 110: 715-719.

141. Shimada YJ, Passeri JJ2, Baggish AL2, O'Callaghan C2, Lowry PA2, et al. (2013) Effects of losartan on left ventricular hypertrophy and fibrosis in patients with nonobstructive hypertrophic cardiomyopathy. JACC Heart Fail 1: 480-487.
142. Heric B, Lytle BW, Miller DP, Rosenkranz ER, Lever HM, et al. (1995) Surgical management of hypertrophic obstructive cardiomyopathy. Early and late results. J Thorac Cardiovasc Surg 110: 195-206.
143. Robbins RC, Stinson EB (1996) Long-term results of left ventricular myotomy and myectomy for obstructive hypertrophic cardiomyopathy. J Thorac Cardiovasc Surg 111: 586-594.
144. Schulte HD, Gramsch-Zabel H, Schwartzkopff B (1995) [Hypertrophic obstructive cardiomyopathy: surgical treatment]. Schweiz Med Wochenschr 125: 1940-1949.
145. Schulte HD, Bircks W, Lösse B (1987) Techniques and complications of transaortic subvalvular myectomy in patients with hypertrophic obstructive cardiomyopathy (HOCM). Z Kardiol 76 Suppl 3: 145-151.
146. Maron BJ, Yacoub M, Dearani JA (2011) Controversies in cardiovascular medicine. Benefits of surgery in obstructive hypertrophic cardiomyopathy: bring septal myectomy back for European patients. Eur Heart J 32: 1055-1058.
147. Morrow AG, Reitz BA, Epstein SE, Henry WL, Conkle DM, et al. (1975) Operative treatment in hypertrophic subaortic stenosis: techniques, and the results of pre and postoperative assessments in 83 patients. Circulation 52: 88-102.
148. Maron BJ, Rastegar H, Udelson JE, Dearani JA, Maron MS (2013) Contemporary surgical management of hypertrophic cardiomyopathy, the need for more myectomy surgeons and disease-specific centers, and the Tufts initiative. Am J Cardiol 112: 1512-1515.
149. McCully RB, Nishimura RA, Tajik AJ, Schaff HV, Danielson GK (1996) Extent of clinical improvement after surgical treatment of hypertrophic obstructive cardiomyopathy. Circulation 94: 467-471.
150. Smedira NG, Lytle BW, Lever HM, Rajeswaran J, Krishnaswamy G, et al. (2008) Current effectiveness and risks of isolated septal myectomy for hypertrophic obstructive cardiomyopathy. Ann Thorac Surg 85: 127-133.
151. Ommen SR, Maron BJ, Olivotto I, Maron MS, Cecchi F, et al. (2005) Long-term effects of surgical septal myectomy on survival in patients with obstructive hypertrophic cardiomyopathy. J Am Coll Cardiol 46: 470-476.
152. Morrow AG, Brockenbrough EC(1961) Surgical Treatment Of Idiopathic Hypertrophic Subaortic Stenosis: Technic And Hemodynamic Results Of Subaortic Ventriculomyotomy. Ann Surg 154: 181-189.
153. Woo A, Williams WG, Choi R, et al. (2005) Clinical and echocardiographic determinants of long-term survival after surgical myectomy in obstructive hypertrophic cardiomyopathy. Circulation 111: 2033–2041.
154. Maron BJ (2007) Surgical myectomy remains the primary treatment option for severely symptomatic patients with obstructive hypertrophic cardiomyopathy. Circulation 116: 196–206.
155. Olivotto I, Ommen SR, Maron MS, Cecchi F, Maron BJ (2007) Surgical myectomy versus alcohol septal ablation for obstructive hypertrophic cardiomyopathy: will there ever be a randomized trial? J Am Coll Cardiol 50: 831–834.
156. Nishimura RA, Ommen SR (2010) Septal reduction therapy for obstructive hypertrophic cardiomyopathy and sudden death: what statistics cannot tell you. Circ Cardiovasc Interv 3: 91-93.
157. Panaich SS, Badheka AO2, Chothani A3, Mehta K4, Patel NJ5, et al. (2014) Results of ventricular septal myectomy and hypertrophic cardiomyopathy (from Nationwide Inpatient Sample [1998-2010]). Am J Cardiol 114: 1390-1395.
158. Ball W, Ivanov J, Rakowski H, Wigle ED, Linghorne M, et al. (2011) Long-term survival in patients with resting obstructive hypertrophic cardiomyopathy comparison of conservative versus invasive treatment. J Am Coll Cardiol 58: 2313-2321.
159. Maron BJ, Nishimura RA, McKenna WJ, Rakowski H, Josephson ME, et al. (1999) Assessment of permanent dual-chamber pacing as a treatment for drug-refractory symptomatic patients with obstructive hypertrophic cardiomyopathy. A randomized, double-blind, crossover study (M-PATHY). Circulation 99: 2927-2933.
160. Boekstegers P, Steinbigler P, Molnar A, Schwaiblmair M, Becker A, et al. (2001) Pressure-guided nonsurgical myocardial reduction induced by small septal infarctions in hypertrophic obstructive cardiomyopathy. J Am Coll Cardiol 38: 846-853.
161. Chang SM, Lakkis NM, Franklin J, Spencer WHIII, Nagueh SF (2004) Predictors of outcome after alcohol septal ablation therapy in patients with hypertrophic obstructive cardiomyopathy. Circulation 109: 824-827.
162. Faber L, Seggewiss H, Gleichmann U (1998) Percutaneous transluminal septal myocardial ablation in hypertrophic obstructive cardiomyopathy: Results with respect to intra-procedural myocardial contrast echocardiography. Circulation 98: 2415-2421.
163. Faber L, Seggewiss H, Ziemssen P (2000) Targeting percutaneous transluminal septal ablation for HOCM by intra-procedural echocardiographic monitoring. J Am Soc Echocardiogr 13: 1074-1079.
164. Faber L, Meissner A, Ziemssen P, Seggewiss H (2000) Percutaneous transluminal septal myocardial ablation for hypertrophic obstructive cardiomyopathy: long term follow up of the first series of 25 patients. Heart 83: 326-331.
165. Flores-Ramirez R, Lakkis NM, Middleton KJ, Killip D, Spencer WH, et al. (2001) Echocardiographic insights into the mechanisms of relief of left ventricular outflow tract obstruction after nonsurgical septal reduction therapy in patients with hypertrophic obstructive cardiomyopathy. J Am Coll Cardiol 37: 208-214.
166. Gietzen FH, Leuner CJ, Raute-Kreinsen U, Dellmann A, Hegselmann J, et al. (1999) Acute and long-term results after transcoronary ablation of septal hypertrophy (TASH). Catheter interventional treatment for hypertrophic obstructive cardiomyopathy. Eur Heart J 20: 1342-1354.
167. Kimmelstiel CD, Maron BJ (2004) Role of percutaneous septal ablation in hypertrophic obstructive cardiomyopathy. Circulation 109: 452-456.
168. Knight CJ, Kurbaan AS, Seggewiss H, Henein M, Gunning M, et al. (1997) Non-surgical septal reduction for hypertrophic

obstructive cardiomyopathy: Outcome in the first series of patients. Circulation 95: 2075-2081.

169. Kuhn H, Gietzen F, Leuner C, Gerenkamp T (1997) Induction of subaortic septal ischaemia to reduce obstruction in hypertrophic obstructive cardiomyopathy. Studies to develop a new catheter-based concept of treatment. Eur Heart J 18: 846-851.
170. Kuhn H, Seggewiss H, Gietzen FH, Boekstegers P, Neuhaus L, et al. (2004) Catheter-based therapy for hypertrophic obstructive cardiomyopathy. First in-hospital outcome analysis of the German TASH Registry. Z Kardiol 93: 23-31.
171. Lakkis NM, Nagueh SF, Kleiman NS, Killip DM, He ZX, et al. (1998) Echocardiography-guided ethanol septal reduction for hypertrophic obstructive cardiomyopathy. Circulation 98: 1750-1755.
172. Nagueh SF, Ommen SR, Lakkis NM, Killip D, Zoghbi WA, et al. (2001) Comparison of ethanol septal reduction therapy with surgical myectomy for the treatment of hypertrophic obstructive cardiomyopathy. J Am Coll Cardiol38: 1707-1710.
173. Qin JX, Shiota T, Lever HM, Asher CR, Popovic ZB, et al. (2004) Conduction system abnormalities in patients with obstructive hypertrophic cardiomyopathy following septal reduction interventions. Am J Cardiol 93: 171-175.
174. Qin JX, Shiota T, Lever HM, Kapadia SR, Sitges M, et al. (2001) Outcome of patients with hypertrophic obstructive cardiomyopathy after percutaneous transluminal septal myocardial ablation and septal myectomy surgery. J Am Coll Cardiol 38: 1994-2000.
175. Seggewiss H, Gleichmann U, Faber L, Fassbender D, Schmidt HK, et al. (1998) Percutaneous transluminal septal myocardial ablation in hypertrophic obstructive cardiomyopathy: Acute results and 3-months follow-up in 25 patients. J Am Coll Cardiol 31: 252-258.
176. Seggewiss H (2001) Current status of alcohol septal ablation for patients with hypertrophic cardiomyopathy. Curr Cardiol Rep 3: 160-166.
177. Spencer WH 3rd, Roberts R (2000) Alcohol septal ablation in hypertrophic obstructive cardiomyopathy: the need for a registry. Circulation 102: 600-601.
178. Sigwart U (1995) Non-surgical myocardial reduction for hypertrophic obstructive cardiomyopathy. Lancet 346: 211-214.
179. Valeti US, Nishimura RA, Holmes DR, Araoz PA, Glockner JF, et al. (2007) Comparison of surgical septal myectomy and alcohol septal ablation with cardiac magnetic resonance imaging in patients with hypertrophic obstructive cardiomyopathy. J Am Coll Cardiol 49: 350-357.
180. Agarwal S, Tuzcu EM, Desai MY, Smedira N, Lever HM, et al. (2010) Updated meta-analysis of septal alcohol ablation versus myectomy for hypertrophic cardiomyopathy. J Am Coll Cardiol 55: 823-834.
181. Noseworthy PA, Rosenberg MA, Fifer MA, Palacios IF, Lowry PA, et al. (2009) Ventricular arrhythmia following alcohol septal ablation for obstructive hypertrophic cardiomyopathy. Am J Cardiol 104: 128-132.
182. Firoozi S, Elliott PM, Sharma S (2002) Septal myotomy-myectomy and transcoronary septal alcohol ablation in hypertrophic obstructive cardiomyopathy: a comparison of clinical, haemodynamic and exercise outcomes. Eur Heart J 23: 1617–24.
183. Sorajja P, Valeti U, Nishimura RA, Ommen SR, Rihal CS, et al. (2008) Outcome of alcohol septal ablation for obstructive hypertrophic cardiomyopathy. Circulation 118: 131-139.
184. Cuoco FA, Spencer WH, Fernandes VL (2008) Implantable cardioverter-defibrillator therapy for primary prevention of sudden death after alcohol septal ablation of hypertrophic cardiomyopathy. J Am Coll Cardiol 52: 1718–1723.
185. Nagueh SF, Groves BM, Schwartz L, Smith KM, Wang A, et al. (2011) Alcohol septal ablation for the treatment of hypertrophic obstructive cardiomyopathy. A multicenter North American registry. J Am Coll Cardiol 58: 2322-2328.
186. Fang MC, Go AS, Chang Y, Borowsky L, Pomernacki NK, et al. (2008) Comparison of risk stratification schemes to predict thromboembolism in people with nonvalvular atrial fibrillation. J Am Coll Cardiol51: 810–815.
187. Di Donna P, Olivotto I, Delcrè SD, Caponi D, Scaglione M, et al. (2010) Efficacy of catheter ablation for atrial fibrillation in hypertrophic cardiomyopathy: impact of age, atrial remodelling, and disease progression. Europace 12: 347-355.
188. Prinz C, Vogt J, Bitter T, Muntean BG, Hering D, et al. (2010) Incidence of adequate ICD interventions in patients with hypertrophic cardiomyopathy supposed to be at high risk for sudden cardiac death. Acta Cardiol 65: 521-525.
189. Faber L, Welge D, Hering D, Butz T, Oldenburg O, et al. (2009) Percutaneous septal ablation after unsuccessful surgical myectomy for patients with hypertrophic obstructive cardiomyopathy. Clin Res Cardiol 97: 899-905.
190. Martin WA, Sigwart U (2002) Who and how to treat with non-surgical myocardial reduction therapy in hypertrophic cardiomyopathy: long-term outcomes. Heart Fail Monit 3: 15-27.
191. Faber L, Welge D, Fassbender D, Schmidt HK, Horstkotte D, et al. (2007) One-year follow-up of percutaneous septal ablation for symptomatic hypertrophic obstructive cardiomyopathy in 312 patients: predictors of hemodynamic and clinical response: Clin Res Cardiol 96: 864-873.
192. Jensen MK, Prinz C, Horstkotte D, van Buuren F, Bitter T, et al. (2013) Alcohol septal ablation in patients with hypertrophic obstructive cardiomyopathy: low incidence of sudden cardiac death and reduced risk profile. Heart 99: 1012-1017.
193. Alam M, Dokainish H, Lakkis N (2006) Alcohol septal ablation for hypertrophic obstructive cardiomyopathy: a systematic review of published studies. J Interv Cardiol 19: 319-327.
194. Fernandes VL, Nielsen CD, Nagueh SF, Herrin AE, Slifka C, et al. (2008) Follow-up of alcohol septal ablation for symptomatic hypertrophic obstructive cardiomyopathy: The Baylor and Medical University of South Carolina experience 1996-2007. J Am Coll Cardiol Intv 1: 561-570.
195. Sorajja P, Ommen SR, Holmes DR Jr, Dearani JA, Rihal CS, et al. (2012) Survival after alcohol septal ablation for obstructive hypertrophic cardiomyopathy. Circulation 126: 2374-2380.
196. Sigwart U (2008) Catheter treatment for hypertrophic obstructive cardiomyopathy: for seniors only? Circulation 118: 107-108.
197. Chen AA, Palacios IF, Mela T, Yoerger DM, Picard MH, et al. (2006) . Acute predictors of subacute complete heart block after alcohol septal ablation for obstructive hypertrophic cardiomyopathy. Am J Cardiol 97: 264-269.
198. Lawrenz T, Lieder F, Bartelsmeier M, Leuner C, Borchert B, et al. (2007) Predictors of complete heart block after transcoronary

ablation of septal hypertrophy: results of a prospective electrophysiological investigation in 172 patients with hypertrophic obstructive cardiomyopathy: J Am Coll Cardiol 49: 2356-2363.

199. ten Cate FJ, Soliman OI, Michels M, Theuns DA, de Jong PL, et al. (2010) Long-term outcome of alcohol septal ablation in patients with obstructive hypertrophic cardiomyopathy: a word of caution. Circ Heart Fail 3: 362-369.
200. Fifer MA (2007) Controversies in cardiovascular medicine. Most fully informed patients choose septal ablation over septal myectomy. Circulation 116: 207-216.
201. Lawrenz T, Borchert B, Leuner C, Bartelsmeier M, Reinhardt J, et al. (2011) Endocardial radiofrequency ablation for hypertrophic obstructive cardiomyopathy: acute results and 6 months' follow-up in 19 patients. J Am Coll Cardiol 57:572–576.
202. Oto A, Aytemir K, Okutucu S, Kaya EB, Deniz A, et al. (2011) Cyanoacrylate for septal ablation in hypertrophic cardiomyopathy. J Interv Cardiol 24: 77-84.
203. Braunwald E (1997) Induced septal infarction: a new therapeutic strategy for hypertrophic obstructive cardiomyopathy. Circulation 95: 1981-1982.