



## Case Report

# Spontaneous Retroperitoneal Hemorrhage: a Case Report and an Overview of the Literature

Daniele Bianchi<sup>1\*</sup>, Eleonora Bernabei<sup>2</sup>, Adriano De Majo<sup>3</sup>, Efstathia Athanasopoulou<sup>2</sup>, Dario Venditti<sup>3</sup> and Silvia Cipriani<sup>2</sup>

<sup>1</sup>Department of Urology, Policlinico Tor Vergata – Rome, Italy

<sup>2</sup>Department of Nephrology and Hypertension, Policlinico Tor Vergata – Rome, Italy

<sup>3</sup>Department of Surgery, Policlinico Tor Vergata – Rome, Italy

\*Corresponding author: Daniele Bianchi, Department of Urology Policlinico Tor Vergata Viale Oxford, 81 – 00133 Rome, Italy, Tel: +39-62-0902977; E-mail: [danielebianchimail@yahoo.it](mailto:danielebianchimail@yahoo.it)

Rec date: March 04, 2015 Acc date: March 30, 2015 Pub date: April 06, 2015

## Abstract

We report the case of a 74-year-old man afflicted with end-stage renal disease, currently in chronic replacement therapy, taking warfarin on a regular basis, who presented feelings of weakness and acute right flank pain during a dialysis session.

He was sent to the Emergency Department where an abdominal computed tomography with intravenous contrast administration revealed the presence of a wide hematoma developing in the right kidney, with continuous extension to perirenal fat tissue, Gerota's fascia and posterior pararenal space.

Given hemodynamic monitoring and serial imaging stability, the patient underwent conservative management with bed rest, antibiotic administration and blood replacement therapy. Warfarin was immediately interrupted. No operative treatment was required. After a consultation with hematologists, long-term replacement of warfarin by heparin calcium was suggested.

Spontaneous retroperitoneal hemorrhage, related to either renal or other structures' bleeding, is a relatively rare event, though potentially life-threatening. It can be due to several underlying conditions. Among them, the patient we are reporting about was afflicted with acquired cystic kidney disease and he was on both long-term dialysis and oral anticoagulant therapy.

In the case of renal hemorrhage with stable hemodynamic conditions and no further suspicious elements, conservative management should be considered.

The patient reported that mild right flank pain started two days before, just some hours after his previous dialysis session, with no further remarkable clinical signs. No prior or recent traumatic event was reported.

In his previous history, he was diagnosed with membranous glomerulonephritis 31 years ago, eventually leading to end-stage renal disease (ESRD); he started peritoneal dialysis 13 years ago. Eleven years ago, the patient was prescribed bicarbonate-hemodialysis with high-biocompatible membranes, switching to post-dilution online-hemodiafiltration the following year.

Each current dialysis session lasts approximately four hours, with administration of 2500 IU of heparin sodium, continuously.

The patient's comorbidities include chronic atrial fibrillation, iatrogenic amiodarone-related hypothyroidism, and ESRD-related anemia. Serology for hepatitis B-C has always been negative. He has never been diagnosed with any rheumatologic disease.

He was prescribed warfarin, with an international normalized ratio ranging 2-3 until the event we are reporting about [1]. The patient's entire therapy is reported in Table 1.

Amiodarone
Warfarin
Levothyroxine
Vitamin D analogues
Phosphorous chelating agents
Erythropoietin stimulating agents

**Table 1:** Drugs taken by the patient at the time of SRH diagnosis.

At the Emergency Department, blood sampling showed a hemoglobin value of 9.2 g/dL, consistent with the patient's chronic anemic condition.

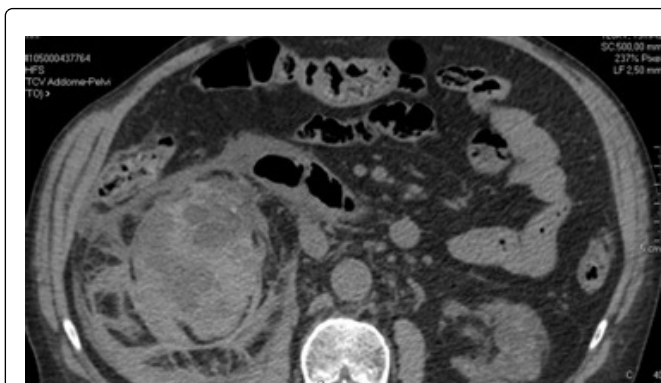
An abdominal computed tomography (CT) with intravenous contrast administration revealed a wide hematoma developing in the right kidney, with continuous extension to perirenal fat tissue, Gerota's fascia, and posterior pararenal space, measuring 20 x 11 x 12 cm approximately (Figure 1). Also, acquired cystic kidney disease (ACKD) was detected.

Warfarin administration was immediately interrupted. An indwelling bladder catheter was placed, with neither urine nor blood output.

The patient underwent constant hemodynamic monitoring and hemochrome tests every six hours, and appeared stable on the first day. The following day, a blood sampling showed hemoglobin values of 7.8 g/dL, and two red blood cell units were transfused.

## Case Report

We report the case of a 74-year-old man who was sent to the Emergency Department of our hospital by the medical staff of our Dialysis Center because of weakness and acute right flank pain during a dialysis session. His blood pressure was 115/90 mmHg, with a pulse rate of 84 bpm and peripheral oxygen saturation above 96%. His body temperature was below 37°C.



**Figure 1:** Perirenal hematoma in CT imaging.

Two days later, the patient was admitted to the Urology Department. Demonstrating hemodynamic stability, he underwent conservative management, with bed rest and a prophylactic ceftriaxone IV for his entire hospital stay.

Subsequently, two days later, blood tests revealed hemoglobin values of 8.0 g/dL with a decreasing trend, thus two further blood units were administered.

Nephrologists planned to treat the patient with his regular dialysis scheme (a 4-hour session three days per week), but they decided not to use anticoagulant drugs during the first 12 sessions.

His hemodynamic parameters have always been stable, with a body temperature constantly below 37° C and normal white blood cell count. No blood output was ever obtained from the bladder catheter.

Ultrasound monitoring showed no remarkable evolution over the following days, and a CT repeated seven days after admission confirmed a stable picture. After a consultation with hematologists, warfarin was chronically replaced by heparin calcium 5000 IU every 12 hours.

Fifteen days after admission, the bladder catheter was removed and the patient was discharged.

He has experienced no further health complications or hospital admissions up until his six-month follow-up.

## Discussion

Spontaneous retroperitoneal hemorrhage (SRH) – also referred to as Wunderlich syndrome in cases of renal bleeding – is a rare entity [2] with an unknown incidence [3] and several causes thought to be responsible.

In a meta-analysis published in 2002, Zhang et al. concluded that renal neoplasms are the most common cause of spontaneous perirenal hemorrhages, and approximately 50% of such neoplasms are malignant [4]. In particular, they highlighted that tumor size is not a good indicator of bleeding risk, given that neoplasms smaller than 4 cm in diameter were just as likely to bleed as bigger tumors.

Angiomyolipomas can be sporadic or associated with tuberous sclerosis [5-7].

Moreover, Zhang et al. concluded polyarteritis nodosa is the most frequent vasculitic disease related to renal hemorrhage, and it must be

taken into account in case of bilateral renal involvement. Nandwani et al. [8] also reported in detail about the correlation between polyarteritis nodosa, other vasculitic conditions and SRH.

By the way, one case of SRH and bilateral ureteral stones in a patient with chronic idiopathic thrombocytopenic purpura has been described [9].

Actually, the meta-analysis by Zhang et al. selected studies involving patients with no history of anticoagulant therapy or renal failure who were on dialysis treatment, which is another big issue with SRH.

In 2009, Malek-Marín et al. presented five cases of SRH in dialysis patients, including three renal in origin, one related to a lumbar vertebral artery and one more probably due to bleeding from the iliopsoas muscle [3]. ACKD was present in the three patients with renal bleeding, according to other papers which reported ACKD in up to 72.1% of cases [10].

Besides, bilateral renal bleeding has been described in patients on hemodialysis affected by bilateral ACKD [11].

On the other hand, dialysis-related amyloidosis (DRA) has been postulated as responsible for renal hemorrhage by Malek-Marín et al. [3], in whose studies four out of five patients had clinical manifestations of DRA. The authors suspected DRA was not mentioned in other papers, thus remaining underestimated. Although recent progress in dialysis therapy has improved survival rates, old age and long-term dialysis can be risky conditions for DRA [12].

In addition, some cases of SRH in dialysis patients with viral hepatitis B-C have been published [3].

A further issue related to dialysis treatment is the administration of anticoagulant agents, which has been related to SRH [3,13,14].

Also, an association between warfarin and SRH has been described in at least one case of SRH due to chromophobe adenocarcinoma [15]; moreover, a case of enoxaparin-associated SRH in pulmonary embolism treatment has been reported [16].

One case of SRH due to right internal artery bleeding in a patient on warfarin and acetyl salicylic acid has been published [17].

Some further miscellaneous events of SRH have been described, such as arteriovenous malformation and renal artery aneurysm, infections [4], lupus nephritis [18], xanthogranulomatous pyelonephritis [19], lower pole artery bleeding in a patient affected by neurofibromatosis type-1 [20], untreated ureteral tumors [21], arteriosclerosis [22], metastatic gestational trophoblastic tumors [23], and hypertension [24,25].

In the literature, few cases have been described as idiopathic [4,26].

Our patient matched more than one of the conditions described in the literature as possible causes of SRH, ranging from hemodialysis and ACKD to therapy with warfarin and heparin. In our opinion, all of them might have contributed to the hemorrhage.

What is of concern to clinical practice is that SRH should always be considered in patients on hemodialysis presenting acute abdominal pain or clinical signs consistent with hemorrhage.

Moreover, although SRH is often related to dramatic symptoms, a subacute, larvate presentation – as in the case we observed – should be taken into account.

Even if abdominal ultrasound scans are effective in some cases [24], the gold standard for the diagnosis of SRH is CT, with magnetic resonance and angiography reserved for selected cases [27,28]. The use of intravenous contrast for abdominal/pelvic CT in Emergency Department varies nationally and most large-scale papers and guidelines refer to renal bleeding due to trauma [29,30].

Accordingly, by way of caution, in our opinion the use of intravenous contrast for SRH may be suggested in order to adequately evaluate sources of active retroperitoneal bleeding.

Treatment of SRH is not standardized, depending on underlying causes and patient's hemodynamic stability. Options include non-operative management, endovascular embolization, and major surgery [5].

Conservative management includes discontinuation of anticoagulants, bed rest, use of vitamin K in case the patient has been on oral anticoagulation, and blood volume replacement [3]. Desmopressin acetate has been administered before [31].

## Conclusions

SRH is a rare, potentially life-threatening condition that is due to several underlying causes. Its clinical manifestation can be variable, subacute at times. The gold standard diagnostic test is CT; although the treatment options are not standardized, conservative management is recommended in case of renal hemorrhage with stable hemodynamic conditions and no further suspicious elements.

## References

- Hirsh J, Fuster V, Ansell J, Halperin JL (2003) American Heart Association/American College of Cardiology Foundation guide to warfarin therapy. *Circulation* 107: 1692-1711.
- Murphy GS, Sparks SE, Goldberg SR, Morton JR (2013) Spontaneous retroperitoneal hemorrhage in a dialysis patient. *The Journal of Emergency Medicine* 44: e217-9.
- Malek-Marín T, Arenas D, Gil T, Moledous A, Okubo M, et al. (2010) Spontaneous retroperitoneal hemorrhage in dialysis: a presentation of 5 cases and review of the literature. *Clin Nephrol* 74: 229-244.
- Zhang JQ, Fielding JR, Zou KH (2002) Etiology of spontaneous perirenal hemorrhage: a meta-analysis. *J Urol* 167: 1593-1596.
- Molina Escudero R, Castillo OA (2013) Spontaneous retroperitoneal haemorrhage of renal origin (Wunderlich syndrome): analysis of 8 cases. *Archivos Españoles de Urología*. 66: 925-929.
- Parekh S, Jolapara M, Shah T, Rajpura H (2014) Emergency embolization of actively bleeding renal angiomyolipoma in a patient of tuberous sclerosis. *Ren Fail* 36: 1114-1118.
- Vaddi SP, Reddy VP, Devraj R (2011) Wunderlich's Syndrome in a Tuberous Sclerosis Patient. *Indian J Surg* 73: 227-229.
- Nandwani GM1, Musker MP, Chaplin BJ, El Madhoun I, Akbani H (2013) Spontaneous perirenal haemorrhage in polyarteritis nodosa. *J Coll Physicians Surg Pak* 23: 445-447.
- Akyüz M, Caliskan S, Kaya C (2012) Bilateral ureteral stones and spontaneous perirenal hematoma in a patient with chronic idiopathic thrombocytopenic purpura. *Korean Journal of Urology* 53: 502-504.
- Ilias G, Stamatiou K, Karanasiou V, Lebreu F, Sofras F (2007) [Spontaneous renal bleeding in a dialysis patient with acquired cystic disease of the kidney: case report and review of the literature]. *G Chir* 28: 377-379.
- Carlson CC, Holsten SJ, Grandas OH (2003) Bilateral renal rupture in a patient on hemodialysis. *Am Surg* 69: 505-507.
- Yamamoto S, Kazama JJ, Narita I, Naiki H, Gejyo F (2009) Recent progress in understanding dialysis-related amyloidosis. *Bone* 45 Suppl 1: S39-42.
- Farooq V, Hegarty J, Chandrasekar T, Lamerton EH, Mitra S, et al. (2004) Serious adverse incidents with the usage of low molecular weight heparins in patients with chronic kidney disease. *American Journal of Kidney Diseases: the official journal of the National Kidney Foundation* 43: 531-537.
- Fan WX, Deng ZX, Liu F, Liu RB, He L, et al. (2012) Spontaneous retroperitoneal hemorrhage after hemodialysis involving anticoagulant agents. *Journal of Zhejiang University. Science* 13: 408-412.
- Tomic M, Ulamec M, Trnski D, Dimanovski J, Spajic M, et al. (2013) Renal adenocarcinoma presenting as a spontaneous perirenal hematoma in a patient on warfarin therapy--case report and literature review. *Collegium Antropologicum* 37: 629-632.
- Besir FH, Gul M, Ornek T, Ozer T, Ucan B, et al. (2011) Enoxaparin-associated giant retroperitoneal hematoma in pulmonary embolism treatment. *North American Journal of Medical Sciences* 3: 524-526.
- Won DY, Kim SD, Park SC, Moon IS, Kim JI (2011) Abdominal compartment syndrome due to spontaneous retroperitoneal hemorrhage in a patient undergoing anticoagulation. *Yonsei Medical Journal* 52: 358-361.
- Chao CT, Wang WJ, Ting JT (2013) Wunderlich syndrome from lupus-associated vasculitis. *Am J Kidney Dis* 61: 167-170.
- Wakasugi E, Kato Y, Yano H, Kanbara N, Kurita T (1996) [Spontaneous renal rupture due to xanthogranulomatous pyelonephritis; a case report]. *Hinyokika Kyo* 42: 47-50.
- Abt D, De Lorenzi D, Nagel W, Schmid HP, Preusser S (2011) Consecutive spontaneous rupture of the lower pole renal artery and main renal artery due to type 1 neurofibromatosis. *Urology* 77: 1339-1340.
- Noda Y, Tujikawa K, Takada S, Sugao H, Itou Y, et al. (2001) [Spontaneous renal rupture resulting from ureteral tumor left untreated for 6 years: a case report]. *Hinyokika Kyo* 47: 265-268.
- Numasato S, Okamoto T, Matsuzaka J (1994) [A case report of spontaneous renal rupture due to arteriosclerosis]. *Hinyokika Kyo* 40: 817-820.
- Vijay RK, Kaduthodil MJ, Bottomley JR, Abdi S (2008) Metastatic gestational trophoblastic tumour presenting as spontaneous subcapsular renal haematoma. *The British Journal of Radiology* 81: e234-7.
- Baishya RK, Dhawan DR, Sabnis RB, Desai MR (2011) Spontaneous subcapsular renal hematoma: A case report and review of literature. *Urol Ann* 3: 44-46.
- Fernández Pello S, Mosquera J, Fernández I, Pérez Carral JR, Benito P, et al. (2013) [Page kidney: subcapsular haematoma and arterial hypertension. A new case report and review of the literature]. *Arch Esp Urol* 66: 593-596.
- Dangle P, Pandya L, Chehval M (2012) Idiopathic non-traumatic spontaneous renal hemorrhage/laceration: a case report and review of the literature. *W V Med J* 108: 24-26.

27. Katabathina VS, Katre R, Prasad SR, Surabhi VR, Shanbhogue AK, et al. (2011) Wunderlich syndrome: cross-sectional imaging review. *Journal of Computer Assisted Tomography* 35: 425-433.
28. Phillips CK, Lepor H (2006) Spontaneous retroperitoneal hemorrhage caused by segmental arterial mediolysis. *Rev Urol* 8: 36-40.
29. Broder JS, Hamedani AG, Liu SW, Emerman CL (2012) Emergency department contrast practices for abdominal/pelvic computed tomography - a national survey and comparison with the american college of radiology appropriateness criteria. *J Emerg Med* 44: 423-433.
30. Serafetinides E, Kitrey ND, Djakovic N, Kuehhas FE, Lumen N, et al. (2015) A Review of the Current Management of Upper Urinary Tract Injuries by the EAU Trauma Guidelines Panel. *Eur Urol*.
31. Stein J, Brewster UC, Perazella MA (2006) Retroperitoneal bleed from acquired renal cysts. *Semin Dial* 19: 256.