

Giant Fibroadenoma of Breast - Case Report

Quader Naseer MD^{1*}, Krishna priya D² and Sanjay K³

¹Ayaan Institute of Medical Sciences, Telangana, India

²Guntur Medical College, Andhra Pradesh, India

³RVM Institute of Medical Sciences and Research Center, Telangana, India

Abstract

Giant fibroadenomas are defined as a size larger than 5cm or weighing more than 500 gms. We report a case of giant fibroadenoma of size 12×13 cm on USG and weighing 560 grams. This type of tumor accounts for 5% of all breast tumors and 0.5-2% of all cases of fibroadenomas.

Keywords: Giant Fibroadenoma, Breast Lesion, Tumors

***Correspondence to:** Quader Naseer MD, Ayaan Institute of medical sciences, Moinabad, Hyderabad, Telangana, India; E-mail: mdquader59@gmail.com

Citation: Quader Naseer MD, Krishna priya D, Sanjay K (2021) Giant Fibroadenoma of Breast - Case Report. J Clin Oncol Ther, Volume 4:1. 123. DOI: <https://doi.org/10.47275/2690-5663-123>

Received: August 05, 2022; **Accepted:** August 24, 2022; **Published:** August 29, 2022

Introduction

Fibroadenomas are the most common benign tumors of the breast under the age of 30. Occasionally, they could show massive growth resulting in Giant Fibroadenomas (GFs). These tumors could rapidly increase in size, stretching the skin and distorting the nipple imitate other breast lesions [1-3]. Our case presents a nulliparous female with a giant fibroadenoma that was excised entirely.

Case Presentation

The patient was a 21-year-lady nulliparous who had become aware of a left breast lump for 2 years. Swelling is insidious in onset gradually increasing in size and attained present size associated with mild pain which is aggravated during her menstrual cycles. She has regular menstrual cycles and was not on any hormone therapy. On examination left breast is asymmetrical with lump of 15×10cm noted occupying all quadrants of breast firm to hard in consistency immobile, nipple areola complex normal, no palpable axillary lymph nodes, right breast is normal. She was advised for USG of both breasts which revealed 12×13×11cm mass occupying entire left breast, to confirm the diagnosis true cut biopsy is advised which revealed features of fibroadenoma. After necessary pre operative workup and consent for surgery she was taken up for excision of fibroadenoma under GA (Figure 1).

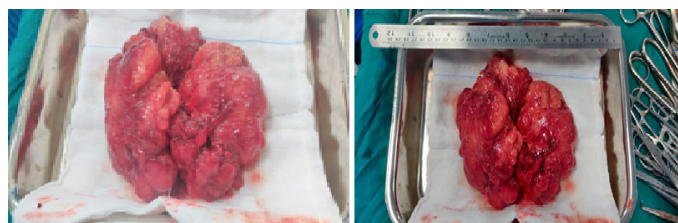


Figure 1: Specimen images.

Intra-operative and post-operative period was uneventful, and she was discharged under stable condition on POD.

She was on regular follow up on POD 7 her wound looked healthy and healing, suture removal was done on POD 7 (Figure 2).

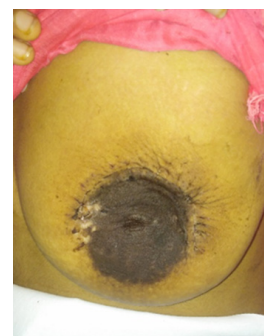

Figure 2: POD 7 Wound.

Discussion

Benign breast lesions are more common breast lesions of which fibroadenoma is more common, variant of fibroadenoma is giant fibroadenoma which is very rare. Giant fibroadenomas are usually encountered in pregnant or lactating women. Their growth is associated with increases in estrogen, progesterone, and prolactin [2]. In our case, the patient was 21 years old and was not lactating or pregnant.

Initially, we suspected a malignant tumour, such as a malignant phyllodes tumour or breast cancer, due to the size and the increase in size [4,5]. US is non-invasive modality and is useful in the diagnosis of lesions in breast tissue. On US, fibroadenomas appear as a well circumscribed round or oval solid mass, with weak internal echoes in a uniform distribution and intermediate acoustic attenuation [6].



Fibroadenomas are often referred to as a breast mouse due to their high mobility. Fibroadenomas are a marble-like mass comprising both epithelial and stromal tissues located under the skin of the breast [7]. These firm, rubbery masses with regular borders are often variable in size. Fibroadenomas can be followed up safely or simply enucleated, while phyllodes tumours must be treated surgically [8]. Furthermore, phyllodes tumours must be resected with adequate margins (the surgical margin is 1 cm) to prevent local recurrence [9,10].

Most cases of giant fibroadenomas can be usually completely excised with preservation of the breast parenchyma and nipple areolar complex, and mastectomy and breast reconstruction are uncommon [3]. Phyllodes tumours occur in patients who are around 10-15 years older than those presenting with fibroadenomas. Fibroadenomas are characterized by well demarcated margins, minimal atypia and rare mitosis while phyllodes tumours sometimes show invasive margins, matrix overgrowth and significant atypia and a leafy structure. US shows a large, lobulated, hypoechoic lesion with echogenic internal septations and increased vascularity occupying the entire left breast; phyllodes tumours are more frequently encountered than fibroadenomas [8]. Sometimes it is difficult to distinguish between these two entities because of the overlap in their imaging features and clinical findings. Because variations in sampling from needle biopsy or core biopsy may yield uncertain results, the final diagnosis is based on the histopathology of the excised lesions. In the present case, the pathological diagnosis of giant fibroadenoma was confirmed after the examination of the surgical specimen.

She was on regular follow up, and her HPE report showed intracanalicular and peri canalicular type of presentation conclusive of fibroadenoma of the left breast.

Conclusion

The majority of breast lesions in young women are identified on an incidental breast exam either by the patient or the healthcare provider.

Breast self-examination plays a major role to avoid missing of any breast lumps at any age in female population. It is estimated that 10% of the world's female population suffers from fibroadenoma once in a lifetime. Even though fibroadenomas are benign lesions, sometimes there may be a need to confirm the histology. An early diagnosis and treatment could prevent this situation and patients should be recommended to undergo reexamination with awareness of progression.

References

1. Morris A, Shaffer K (2007) Recurrent bilateral giant fibroadenomas of the breasts. *Radiol Case Rep* 2: 96. <https://doi.org/10.2484/rcr.v2i3.96>
2. McCague A, Davis JV (2010) Giant fibroadenoma in a 22 year old patient: case report and literature review. *Breast Dis* 31: 49-52. <https://doi.org/10.3233/BD-2009-0288>
3. Park CA, David LR, Argenta LC (2006) Breast asymmetry: presentation of a giant fibroadenoma. *Breast J* 12: 451-461. <https://doi.org/10.1111/j.1075-122X.2006.00303.x>
4. Greenberg R, Skornick Y, Kaplan O (1998) Management of breast fibroadenomas. *J Gen Internal Med* 13: 640-645. <https://doi.org/10.1046/j.1525-1497.1998.cr188.x>
5. Santen RJ, Mansel R (2005) Benign breast disorders. *N Engl J Med* 353: 275-285. <https://doi.org/10.1056/NEJMra035692>
6. Cerrato F, Labow BI (2013) Diagnosis and management of fibroadenomas in the adolescent breast. *Semin Plast Surg* 27: 23-25. <https://doi.org/10.1055/s-0033-1343992>
7. Javed A, Jenkins SM, Labow B, Boughey JC, Lemaine V, et al. (2019) Intermediate and long-term outcomes of fibroadenoma excision in adolescent and young adult patients. *Breast J* 25: 91-95. <https://doi.org/10.1111/tbj.13159>
8. Sosin M, Pulcrano M, Feldman ED, Patel KM, Nahabedian MY, et al. (2015) Giant juvenile fibroadenoma: a systematic review with diagnostic and treatment recommendations. *Gland Surg* 4: 312-321. <https://doi.org/10.3978/j.issn.2227-684X.2015.06.04>
9. Estevão RA, Nazário AC, Baracat EC (2007) Effect of oral contraceptive with and without associated estriol on ultrasound measurements of breast fibroadenoma: randomized clinical trial. *Sao Paulo Med J* 125: 275-280. <https://doi.org/10.1590/S1516-31802007000500005>
10. Bildircin FD, Özdemir A, Karli P, Çetinkaya MB (2019) Breast cancer and ovulation induction. *J Surg Med* 3: 612-618. <https://doi.org/10.28982/josam.605570>